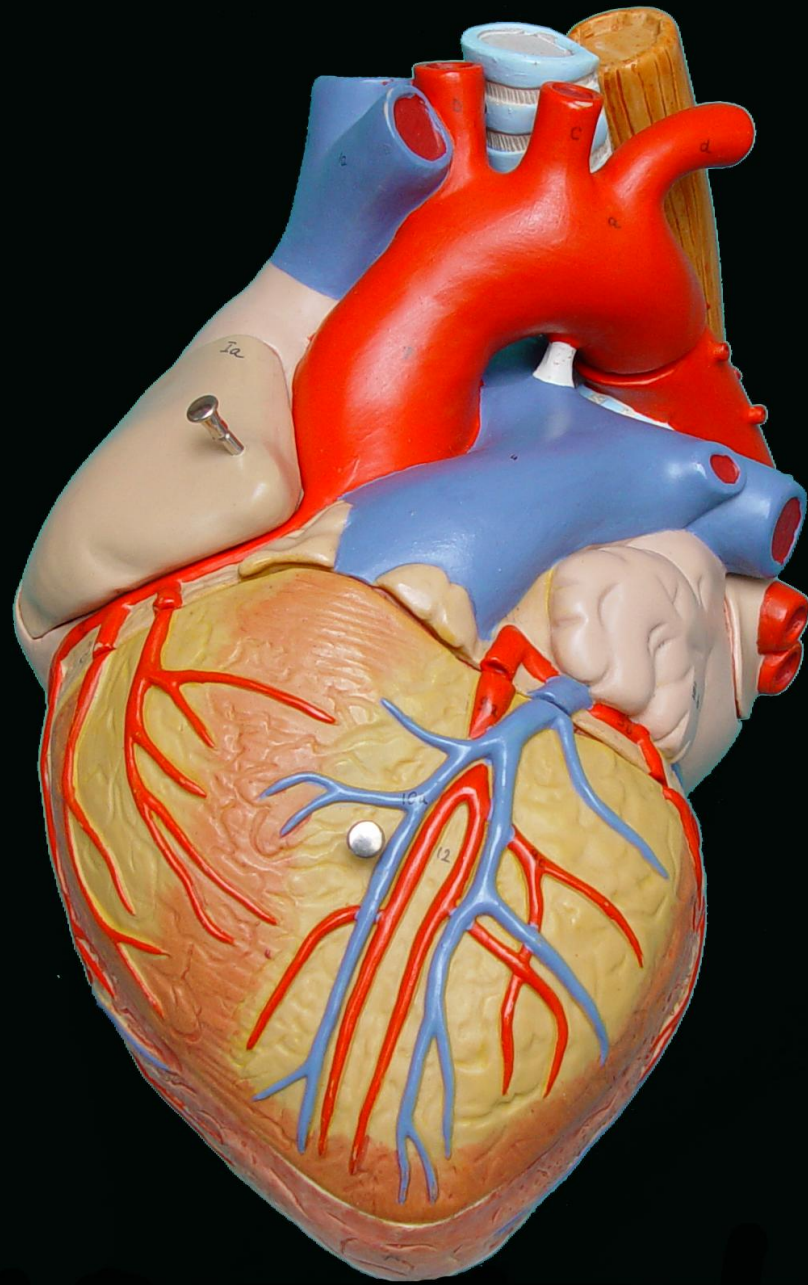


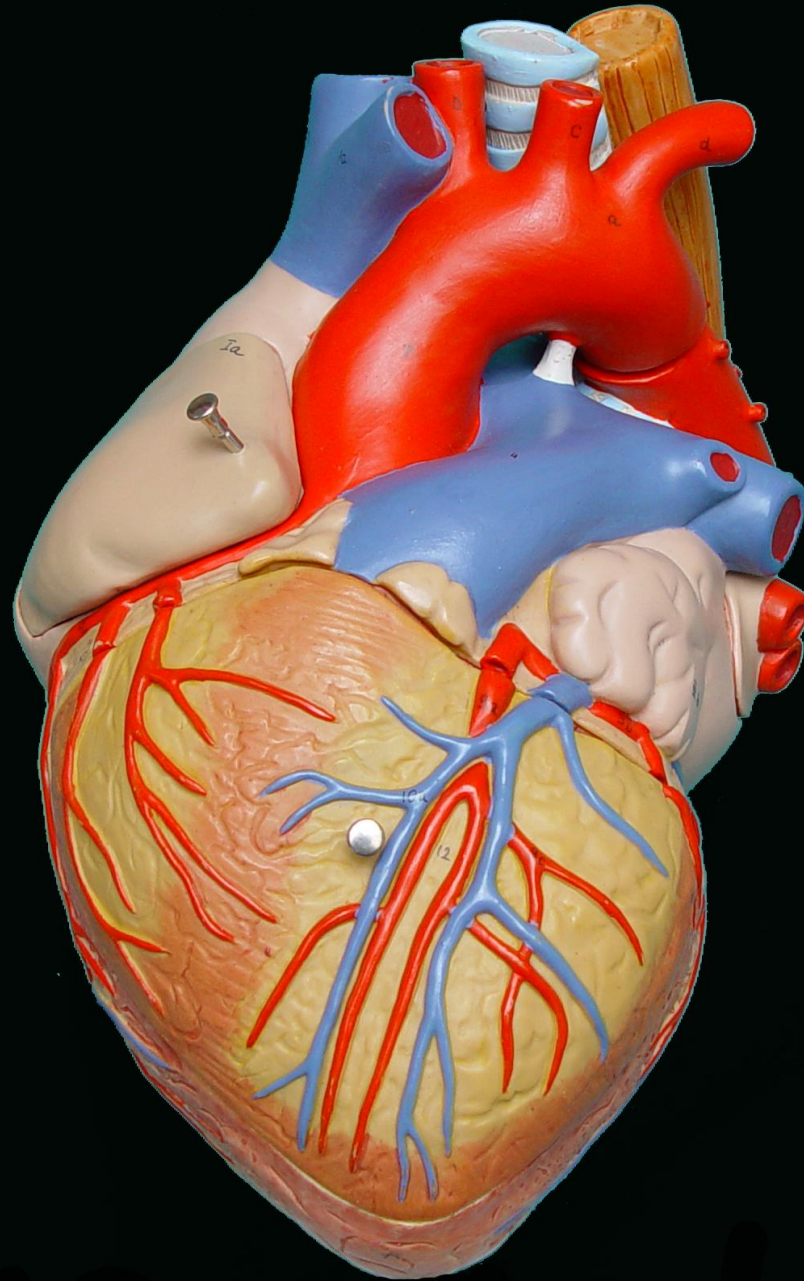
PRÁCTICAS

CORAZÓN

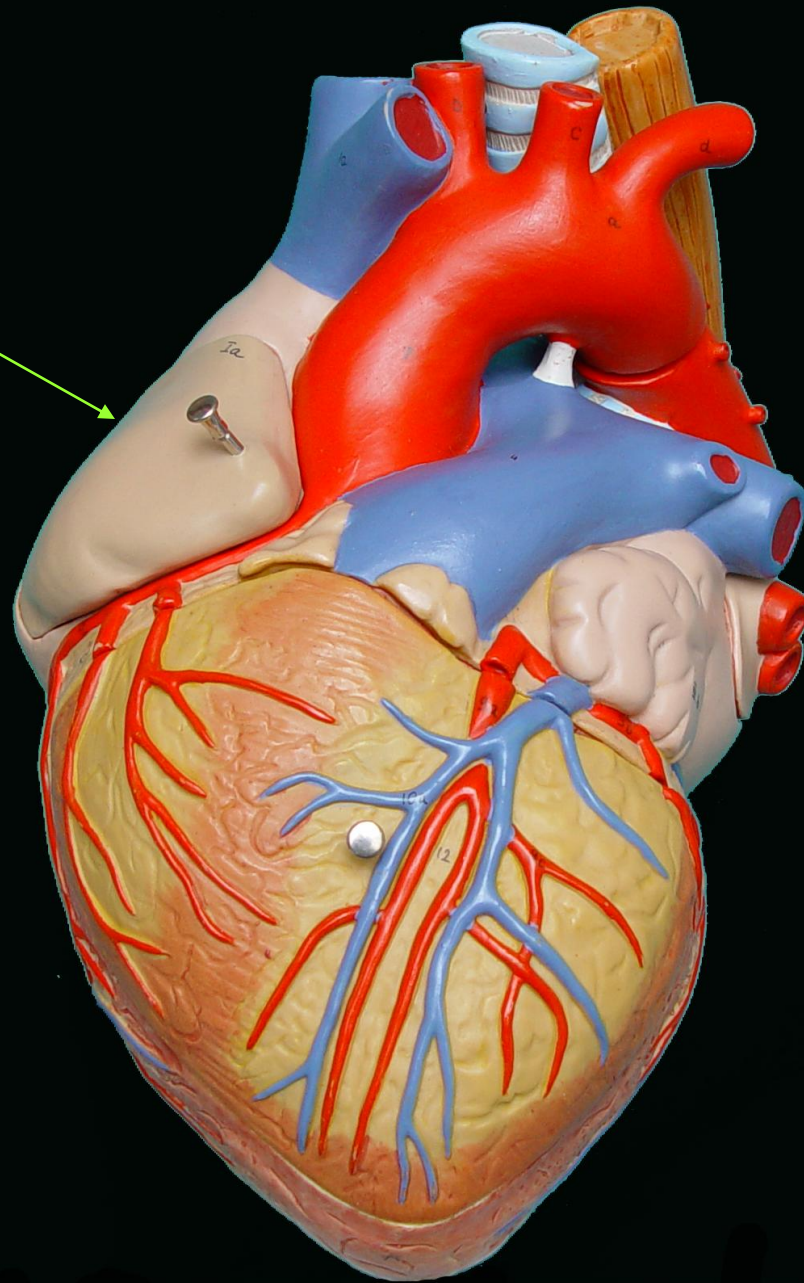
ANATOMÍA I (MEDICINA)



SUPERFICIE ANTERIOR DEL CORAZÓN

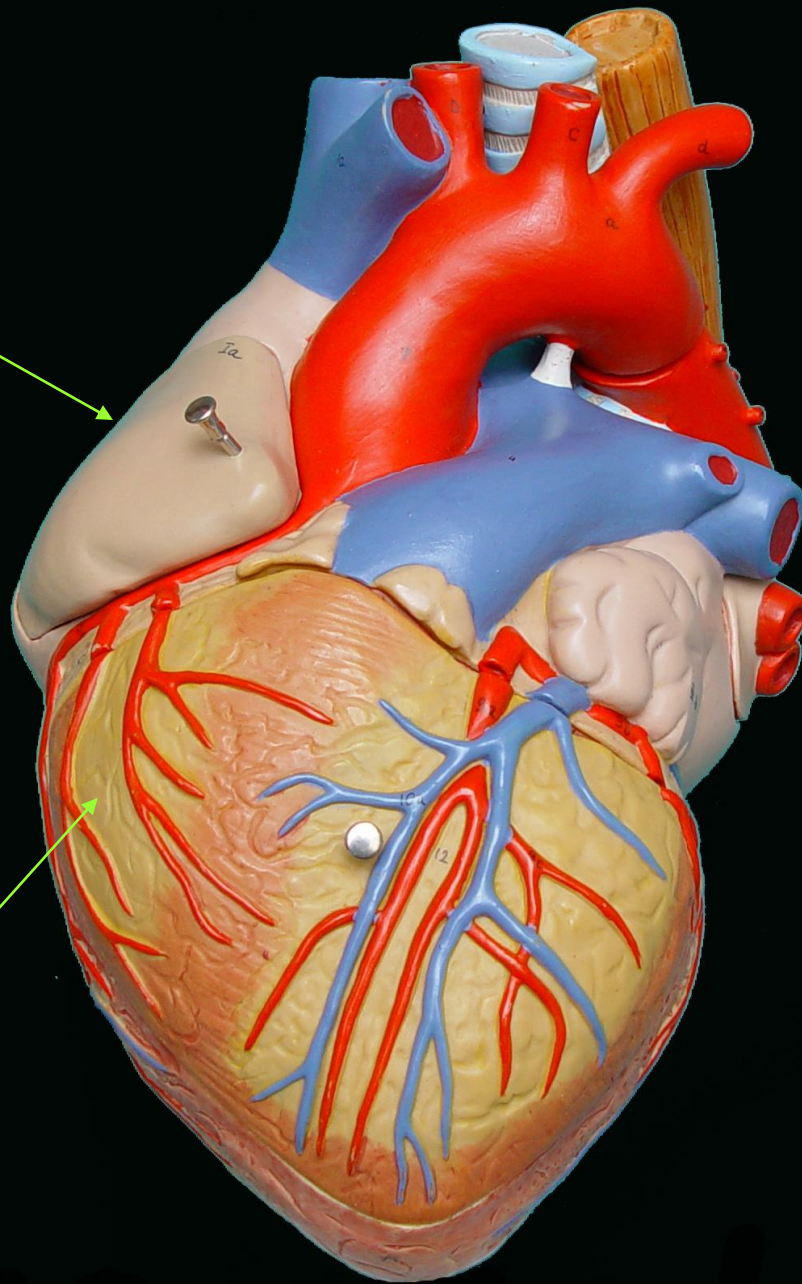


AURICULA
DERECHA



AURICULA
DERECHA

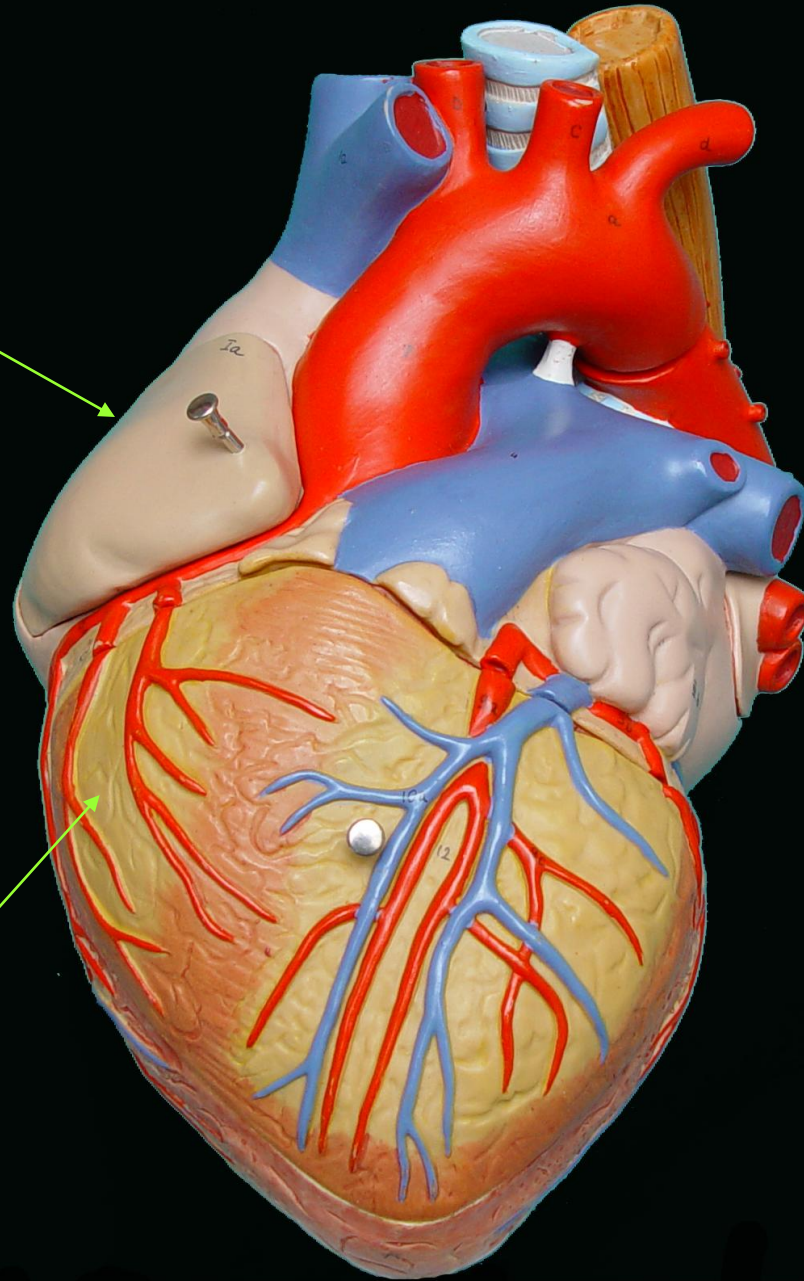
VENTRICULO
DERECHO



AURICULA
DERECHA

AURICULA
IZQUIERDA

VENTRICULO
DERECHO

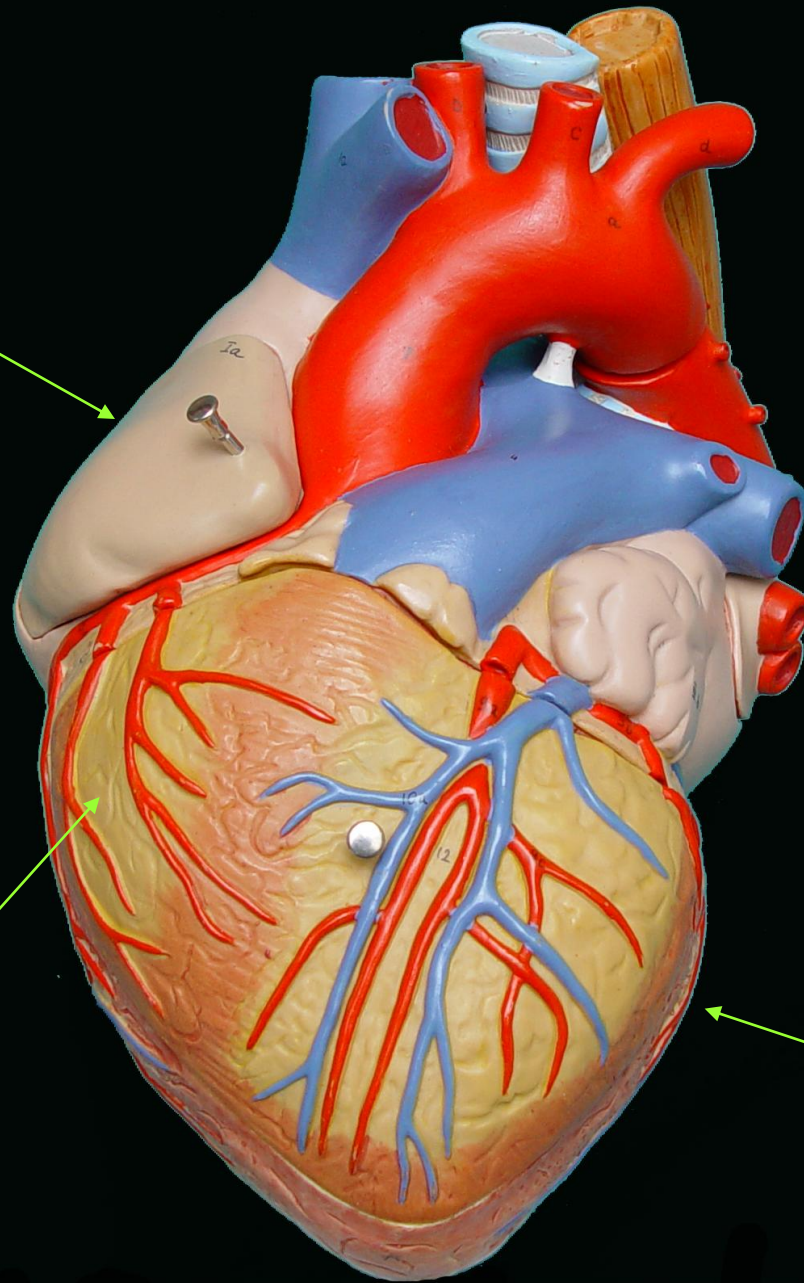


AURICULA
DERECHA

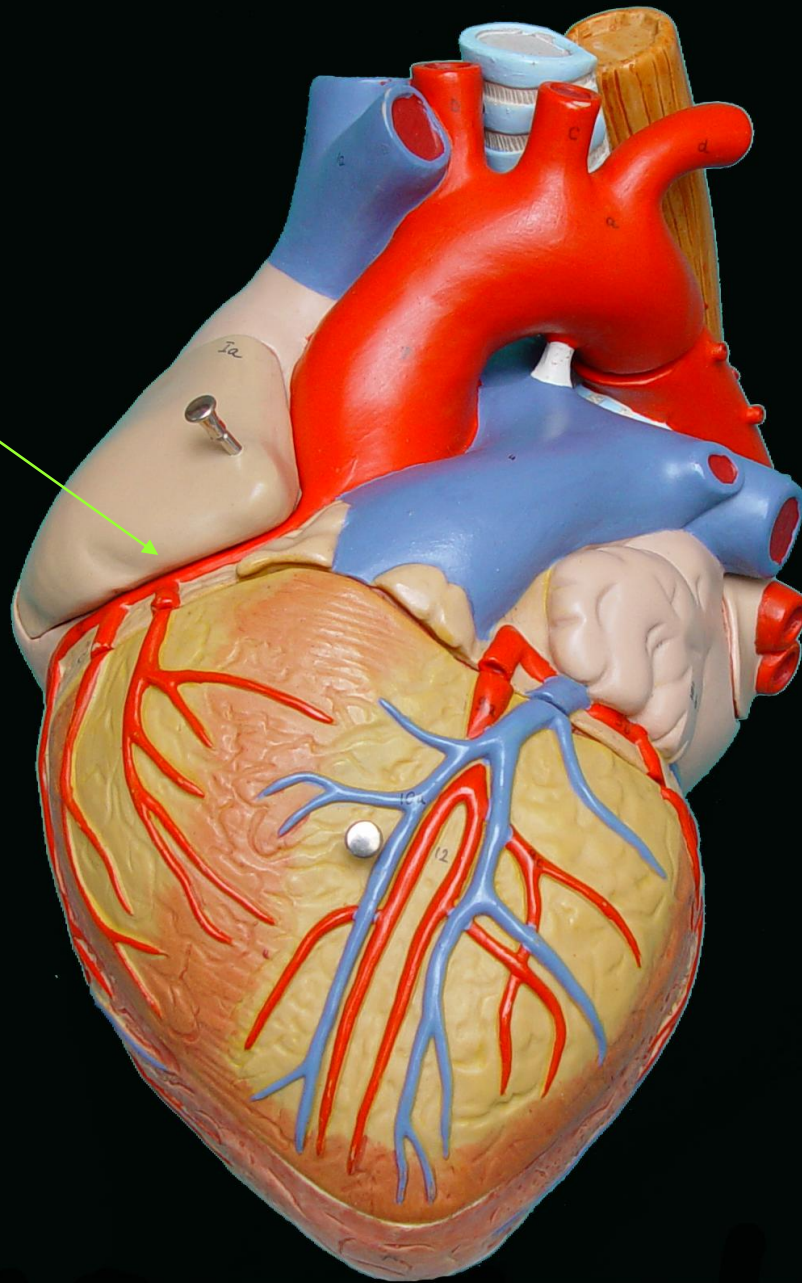
AURICULA
IZQUIERDA

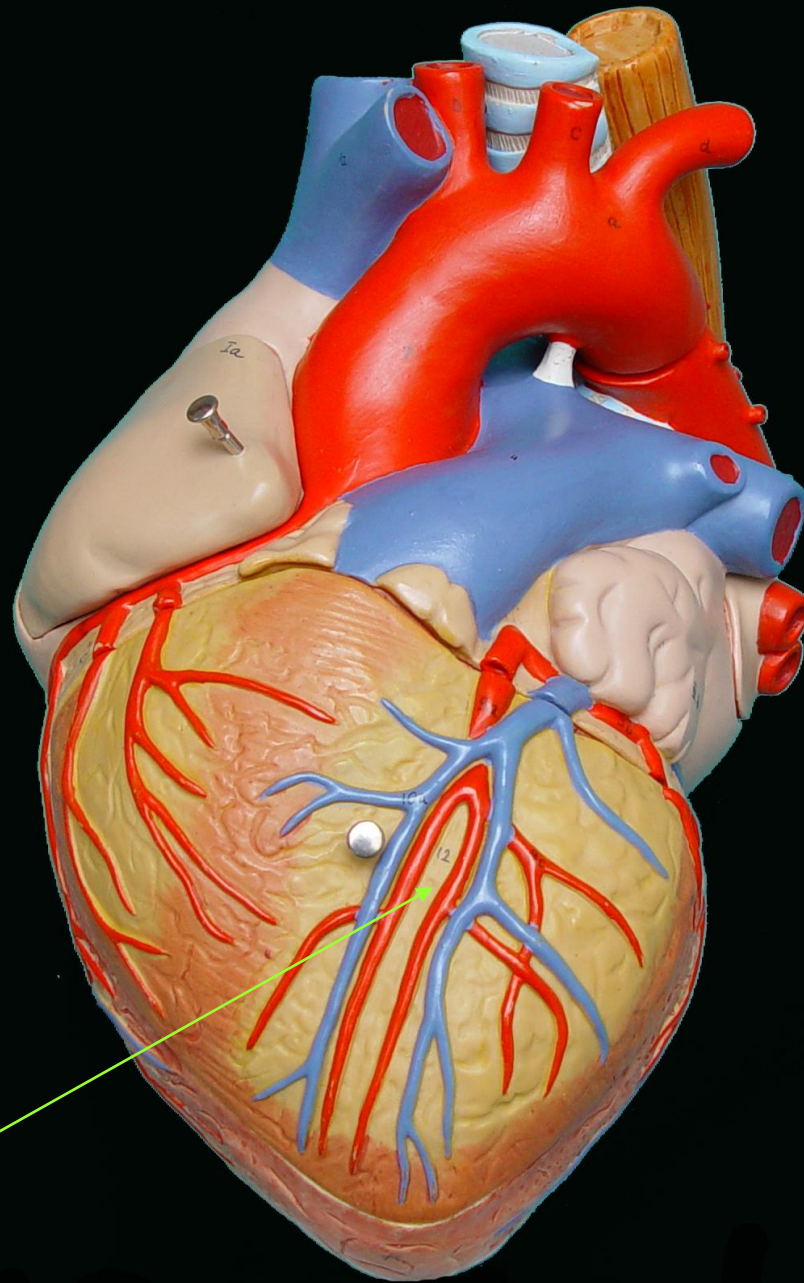
VENTRICULO
DERECHO

VENTRICULO
IZQUIERDO

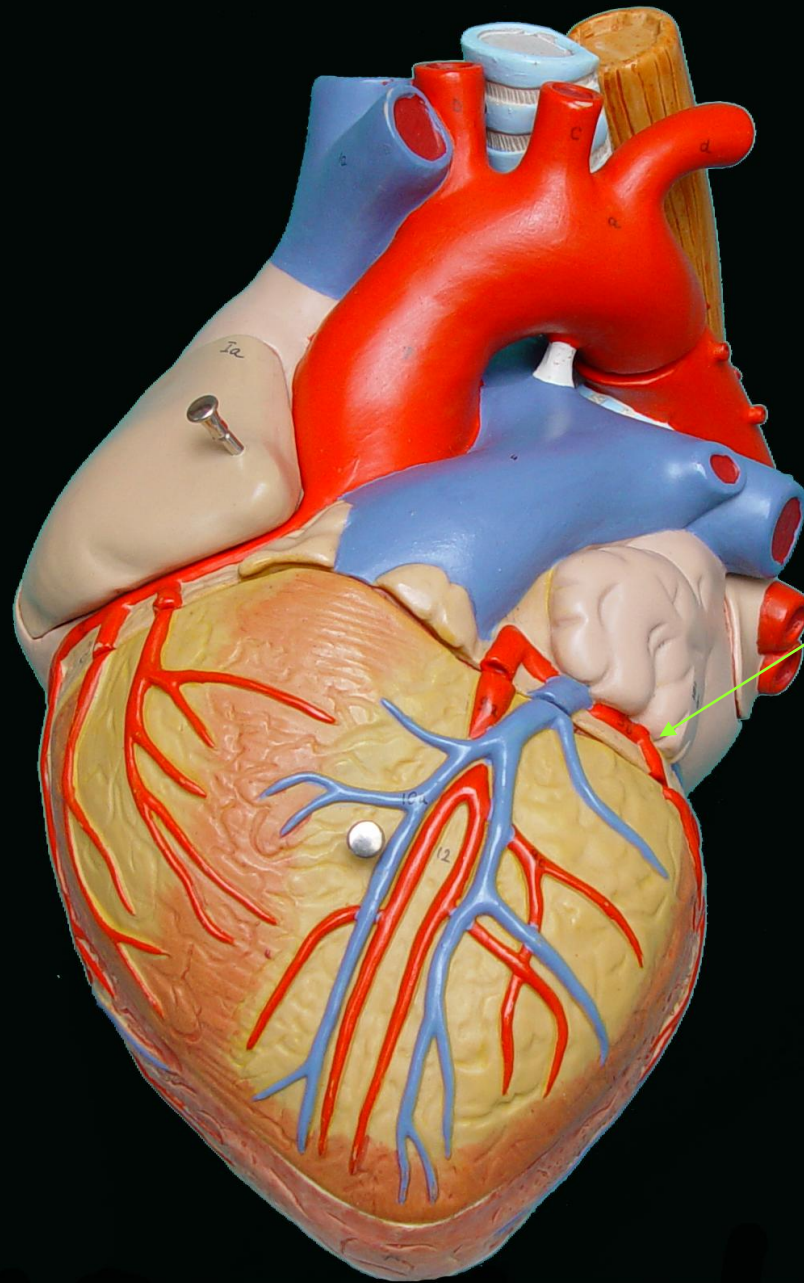


SURCO
AURICULO
VENTRICULAR
DERECHO

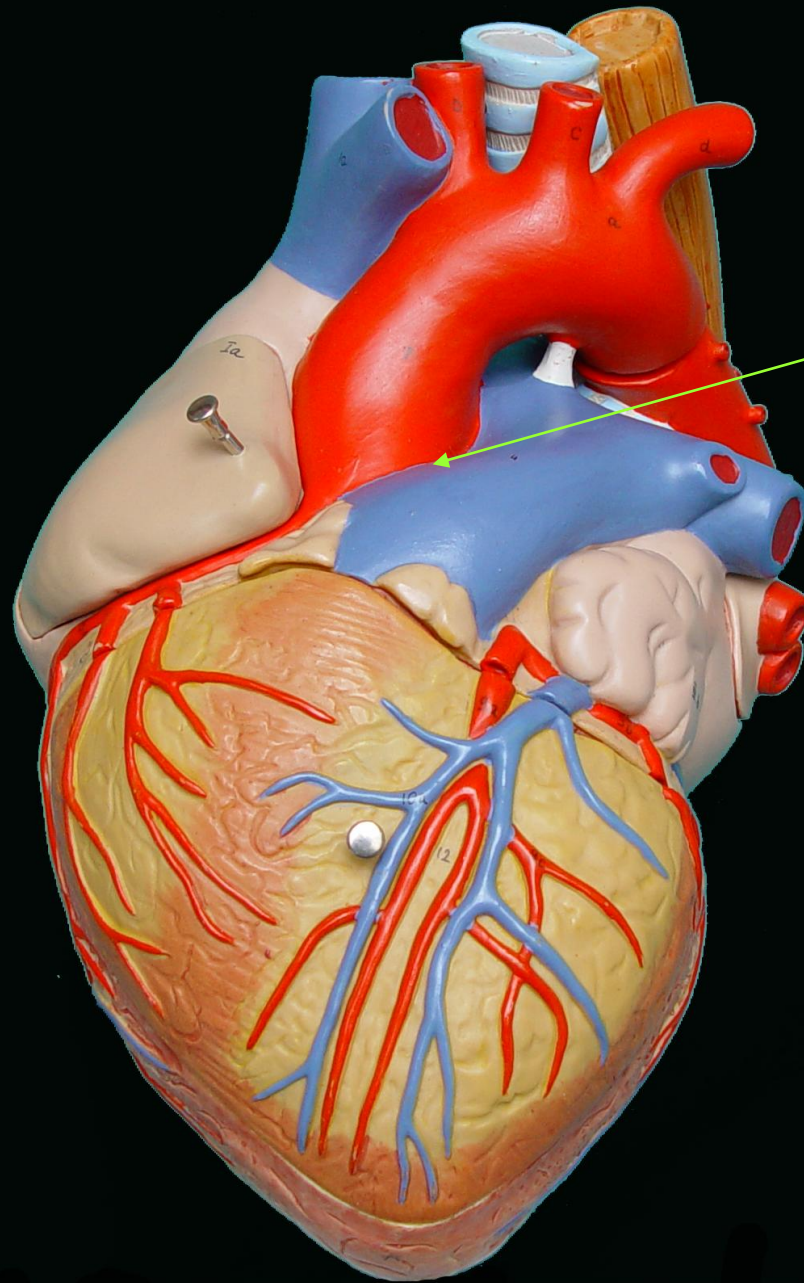




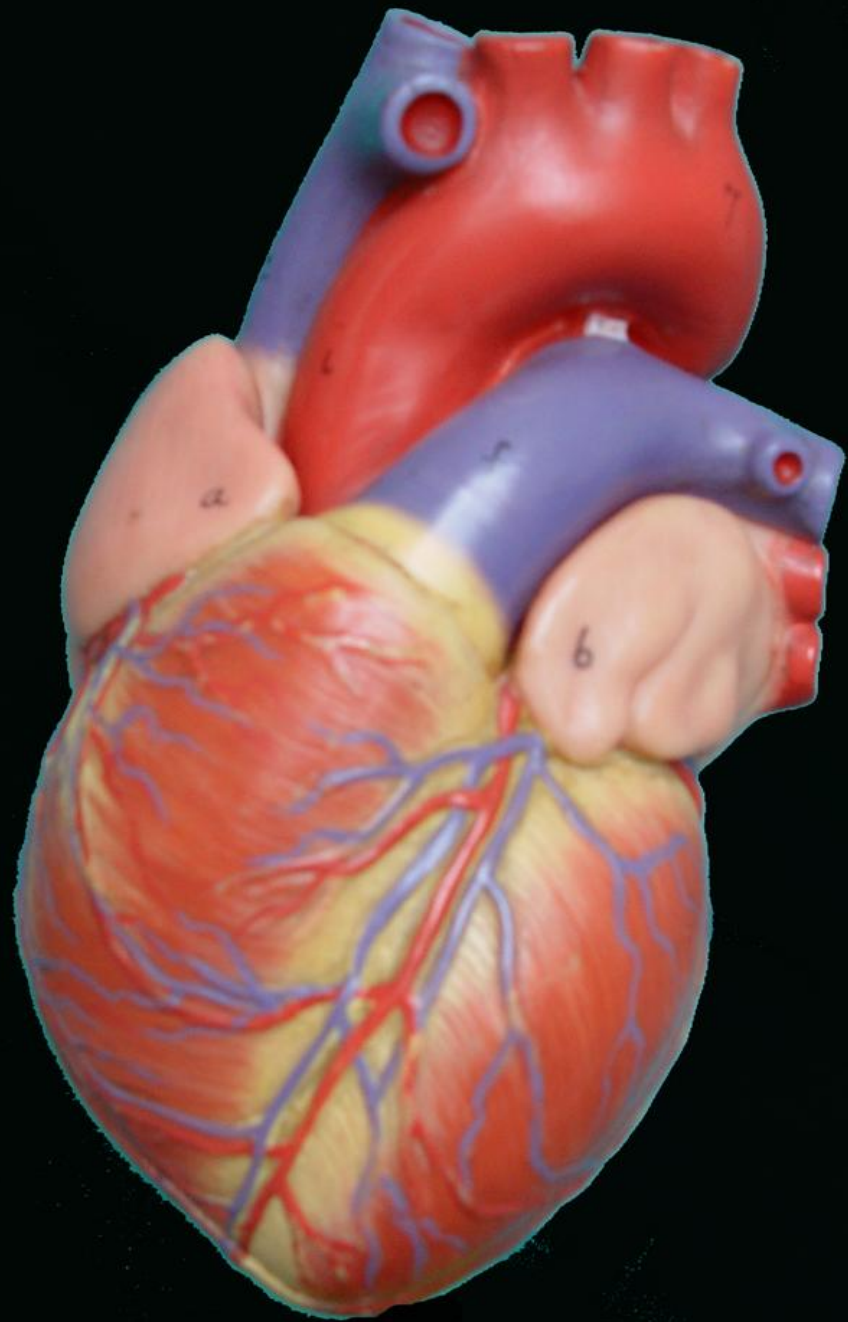
SURCO
INTER-
VENTRICULAR
ANTERIOR



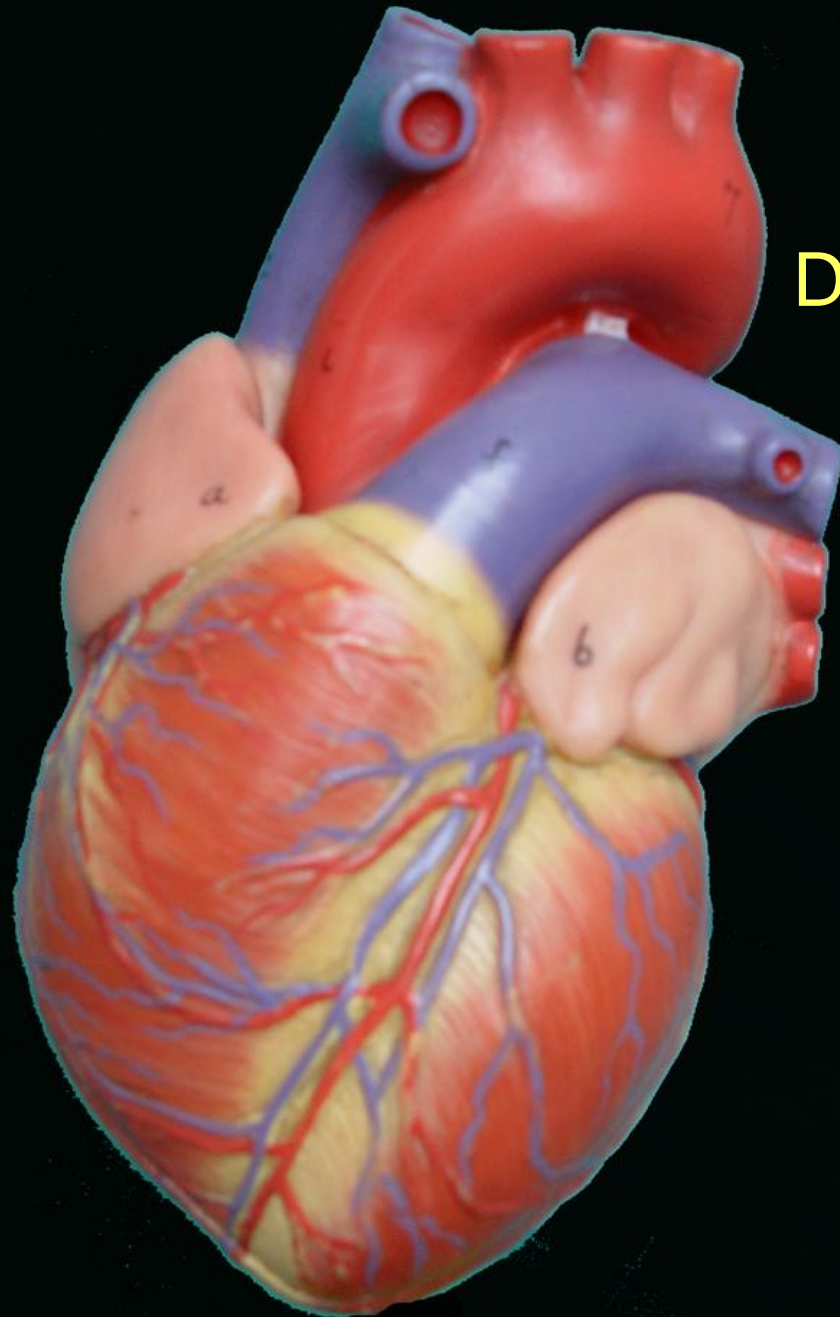
SURCO
AURICULO
VENTRICULAR
IZQUIERDO



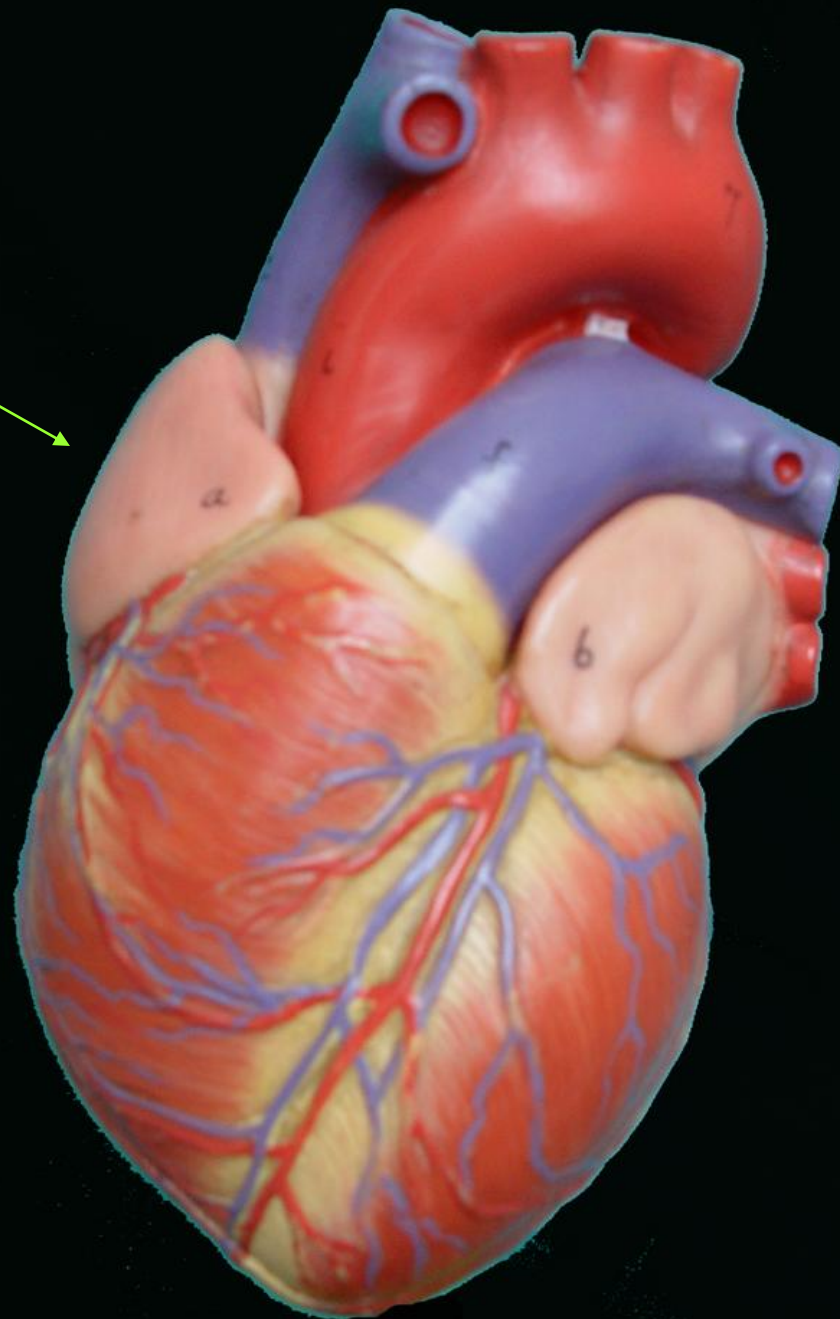
SURCO
INTER-
AURICULAR
ANTERIOR



**SUPERFICIE
ANTERIOR
DEL CORAZÓN**



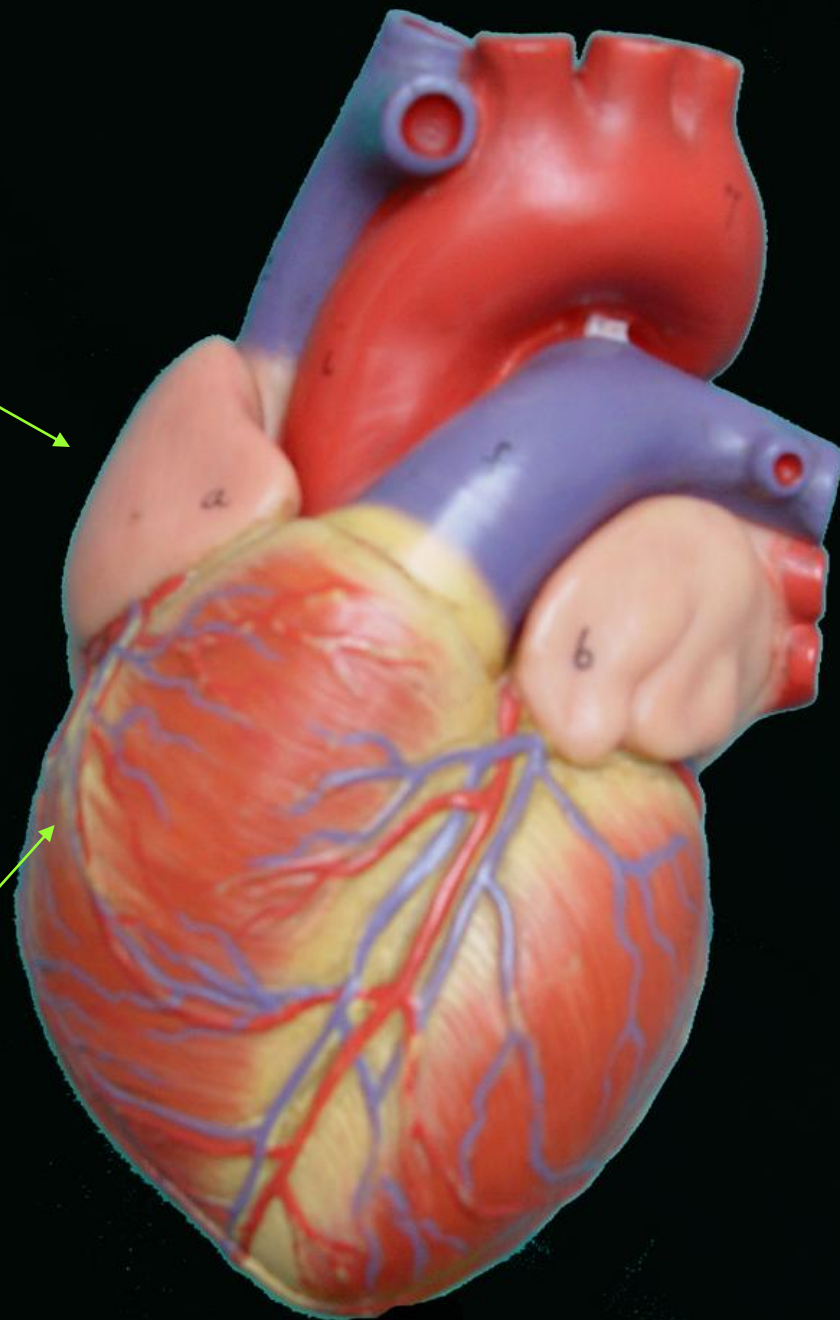
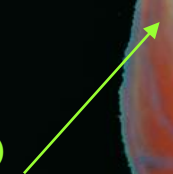
AURICULA
DERECHA



AURICULA
DERECHA



VENTRICULO
DERECHO



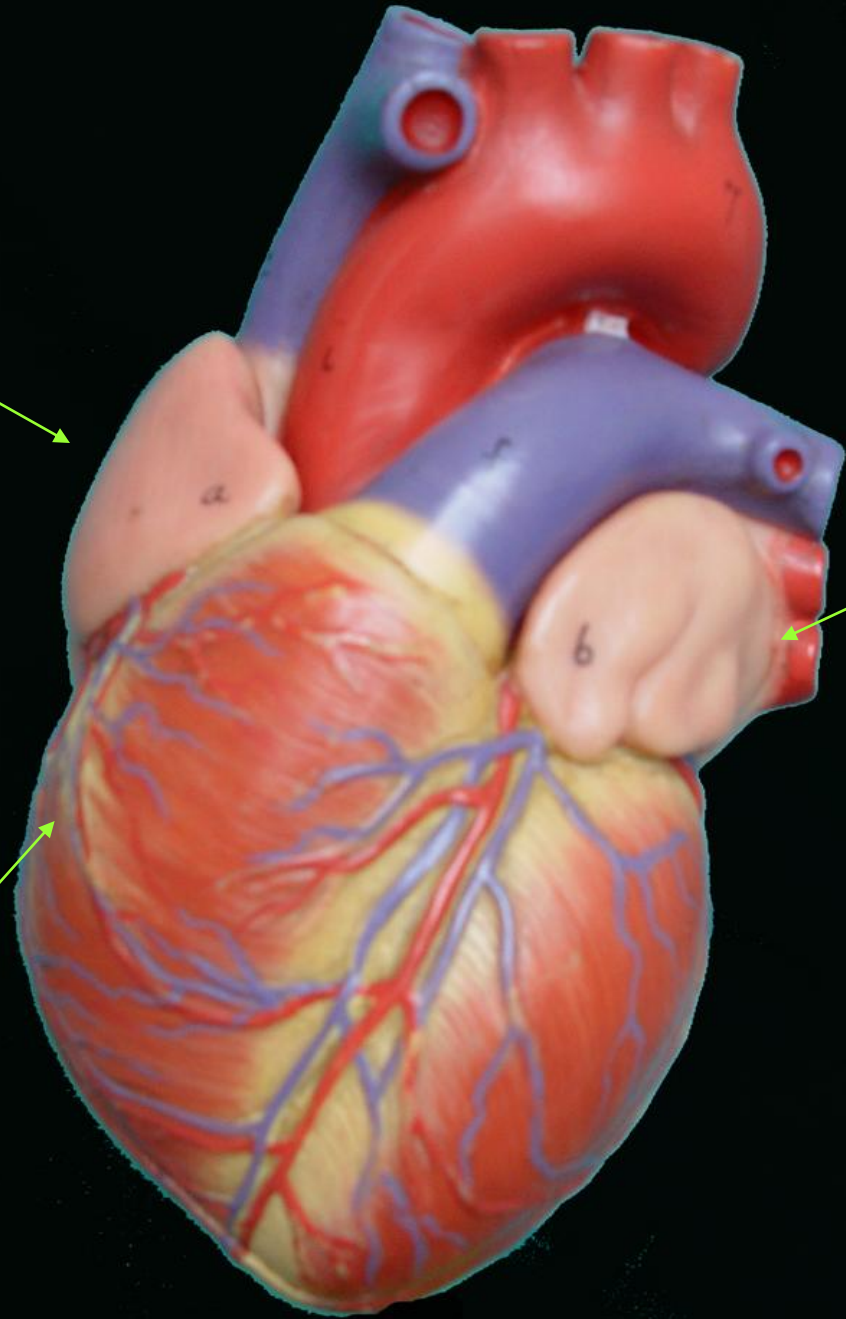
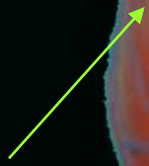
AURICULA
DERECHA



AURICULA
IZQUIERDA



VENTRICULO
DERECHO



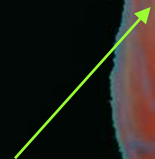
AURICULA
DERECHA



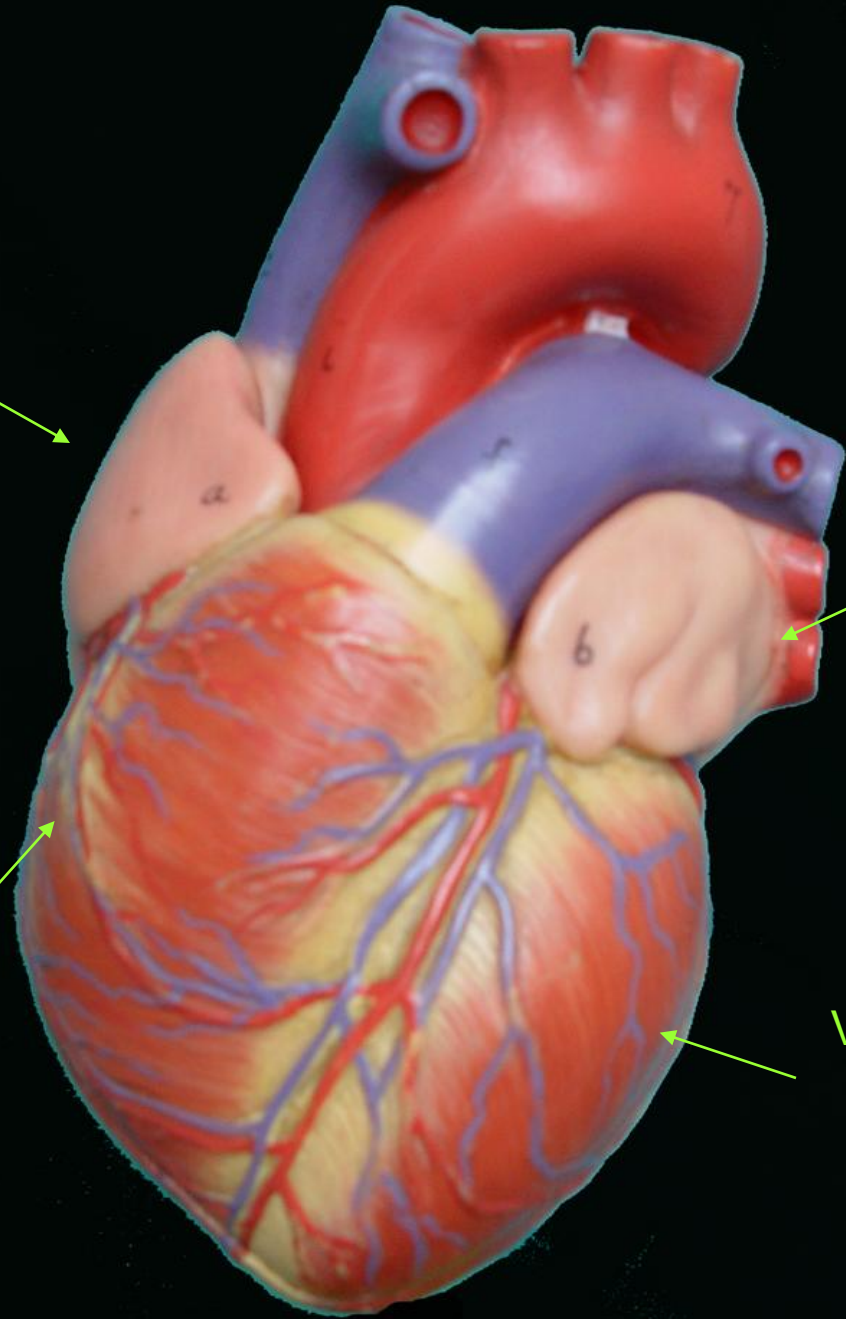
AURICULA
IZQUIERDA



VENTRICULO
DERECHO



VENTRICULO
IZQUIERDO



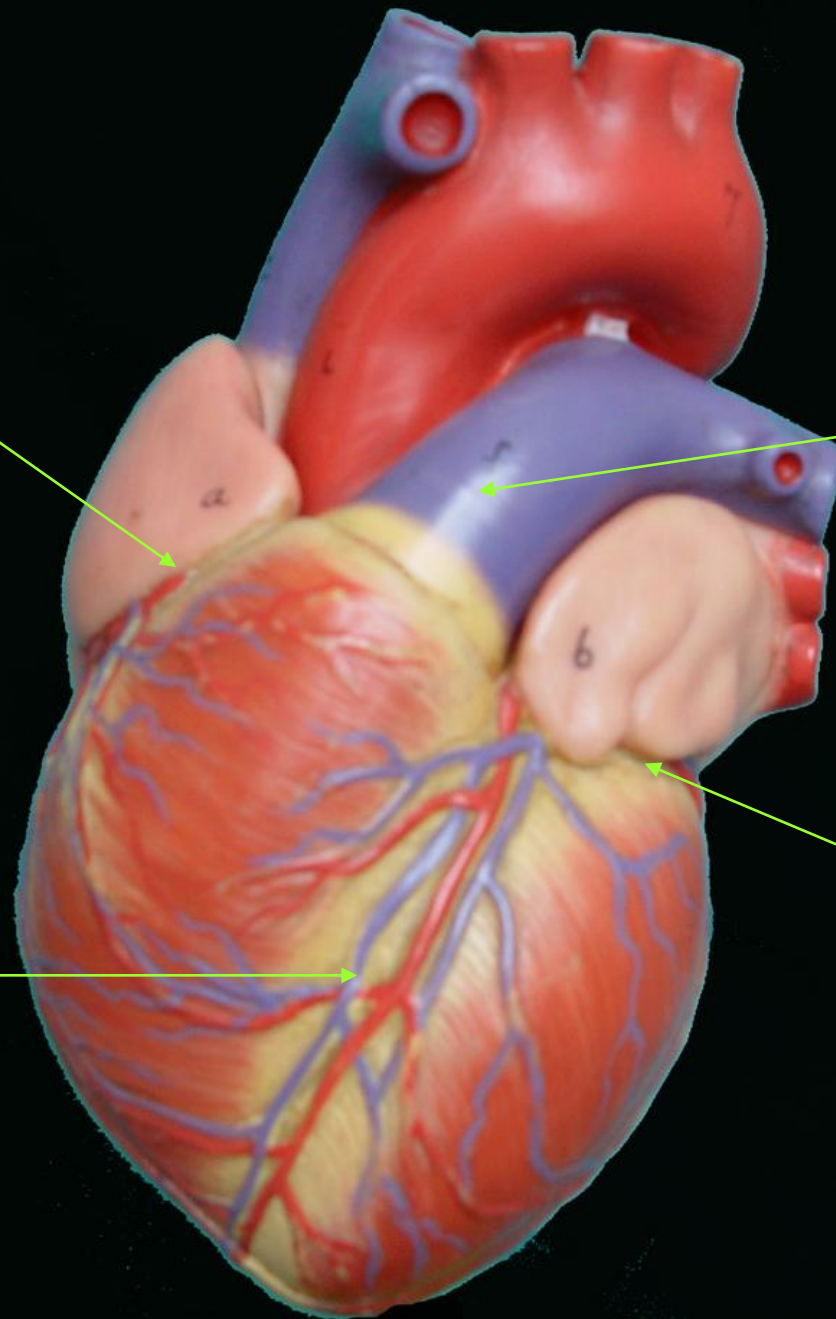
SURCOS

AURICULO-
VENTRICULAR
DERECHO

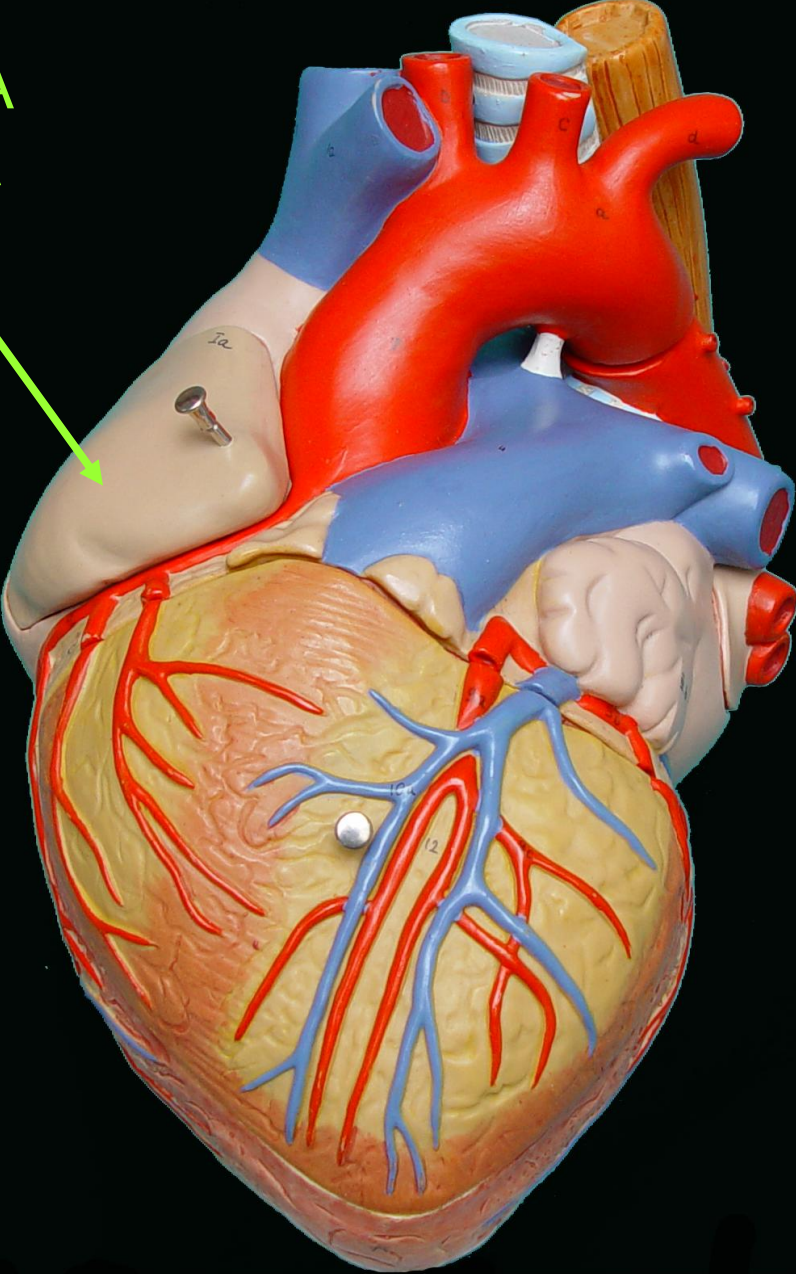
INTER-
AURICULAR
ANTERIOR

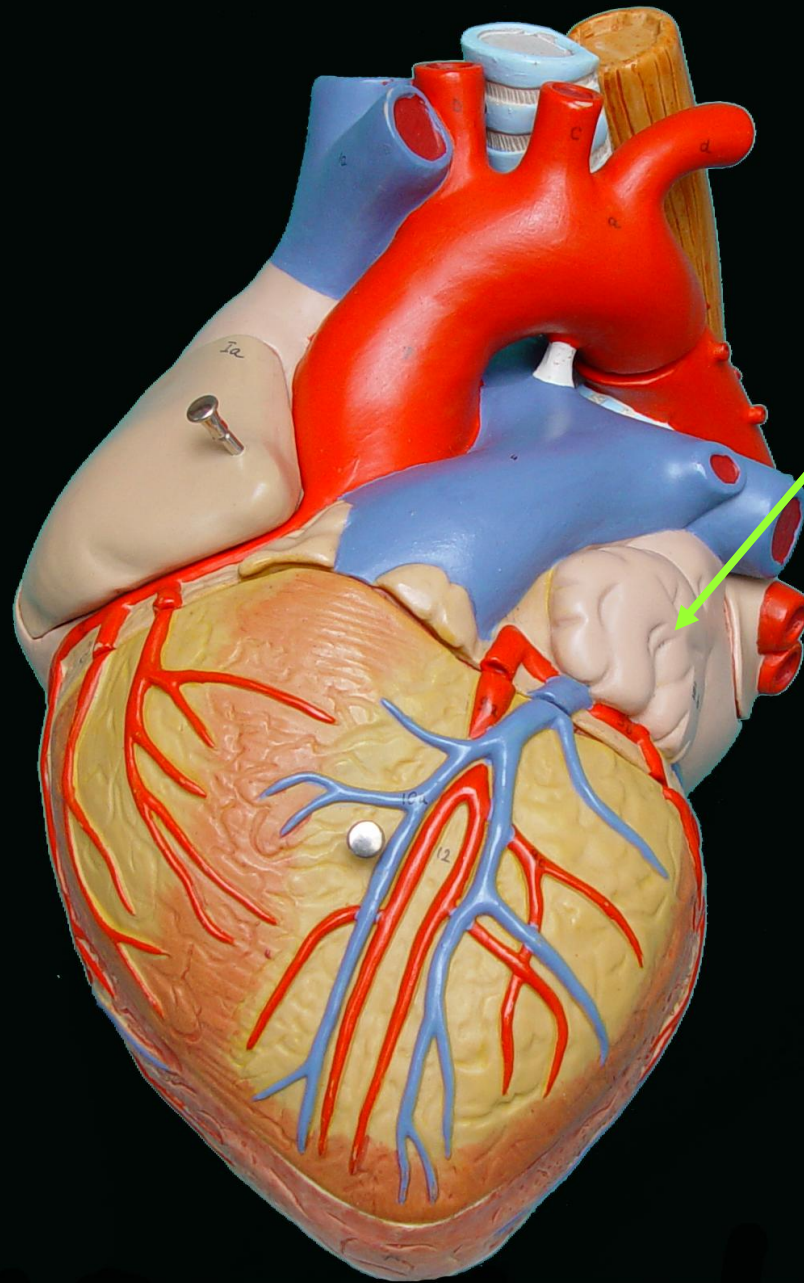
AURICULO
VENTRICULAR
IZQUIERDO

INTER-
VENTRICULAR
ANTERIOR



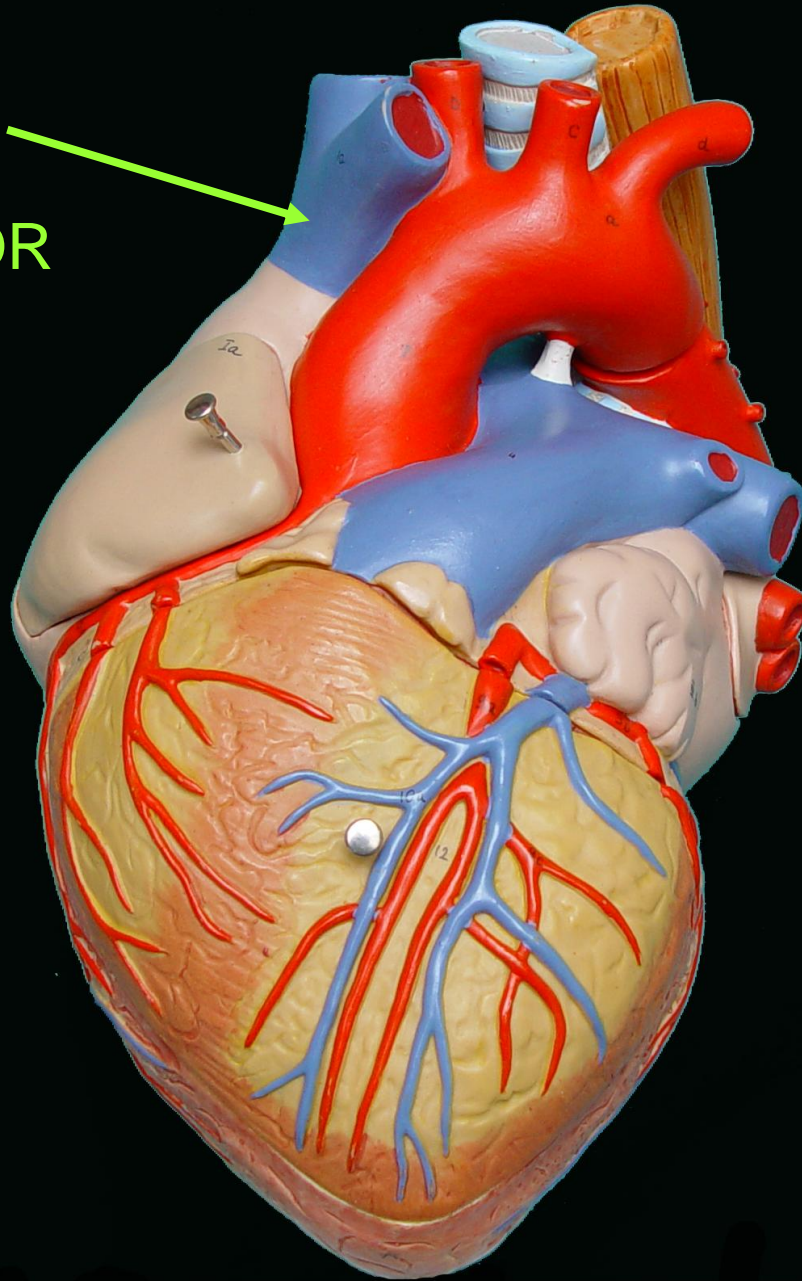
OREJUELA
DERECHA



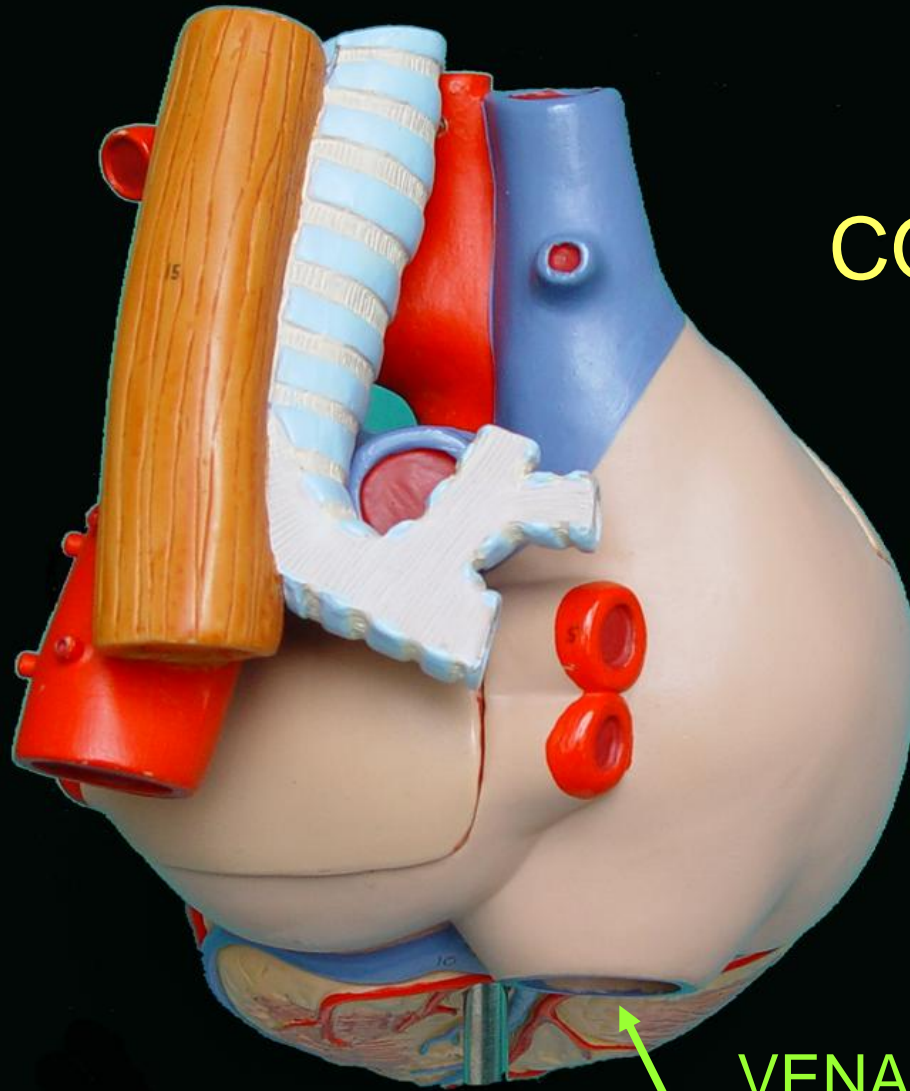


OREJUELA
IZQUIERDA

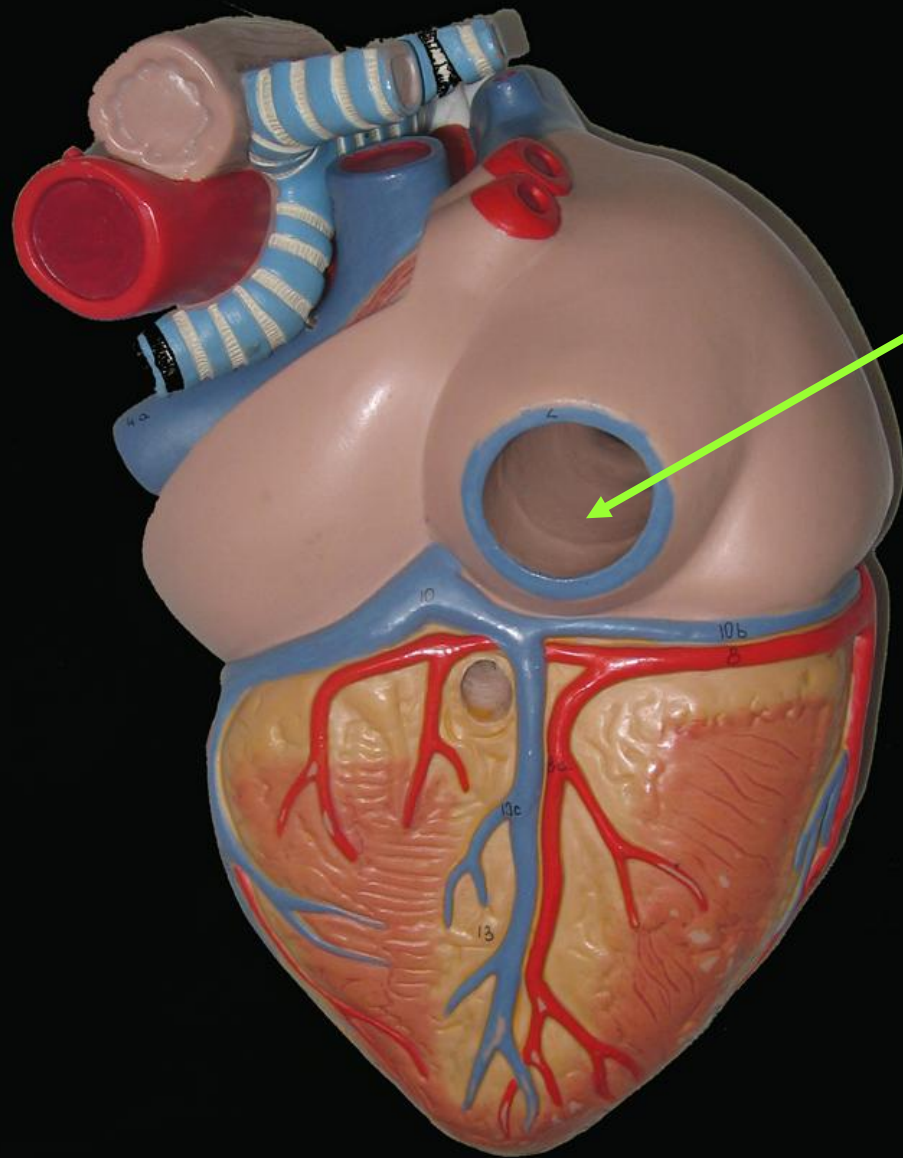
VENA
CAVA
SUPERIOR



BASE DEL CORAZÓN

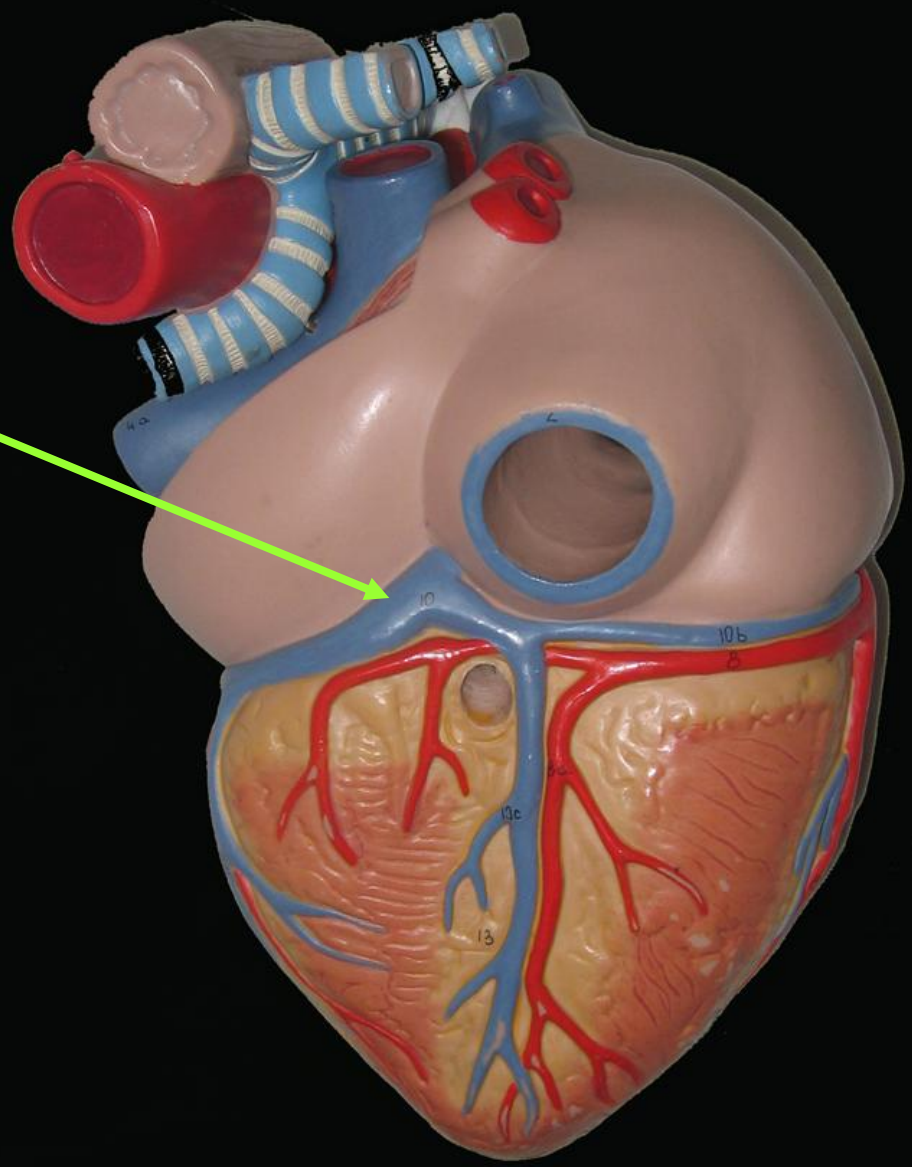
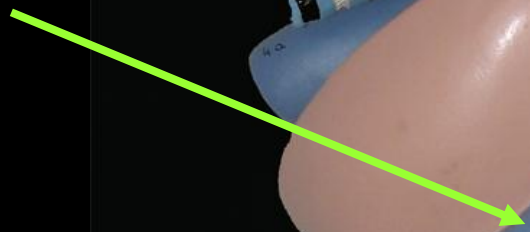


VENA
CAVA
INFERIOR

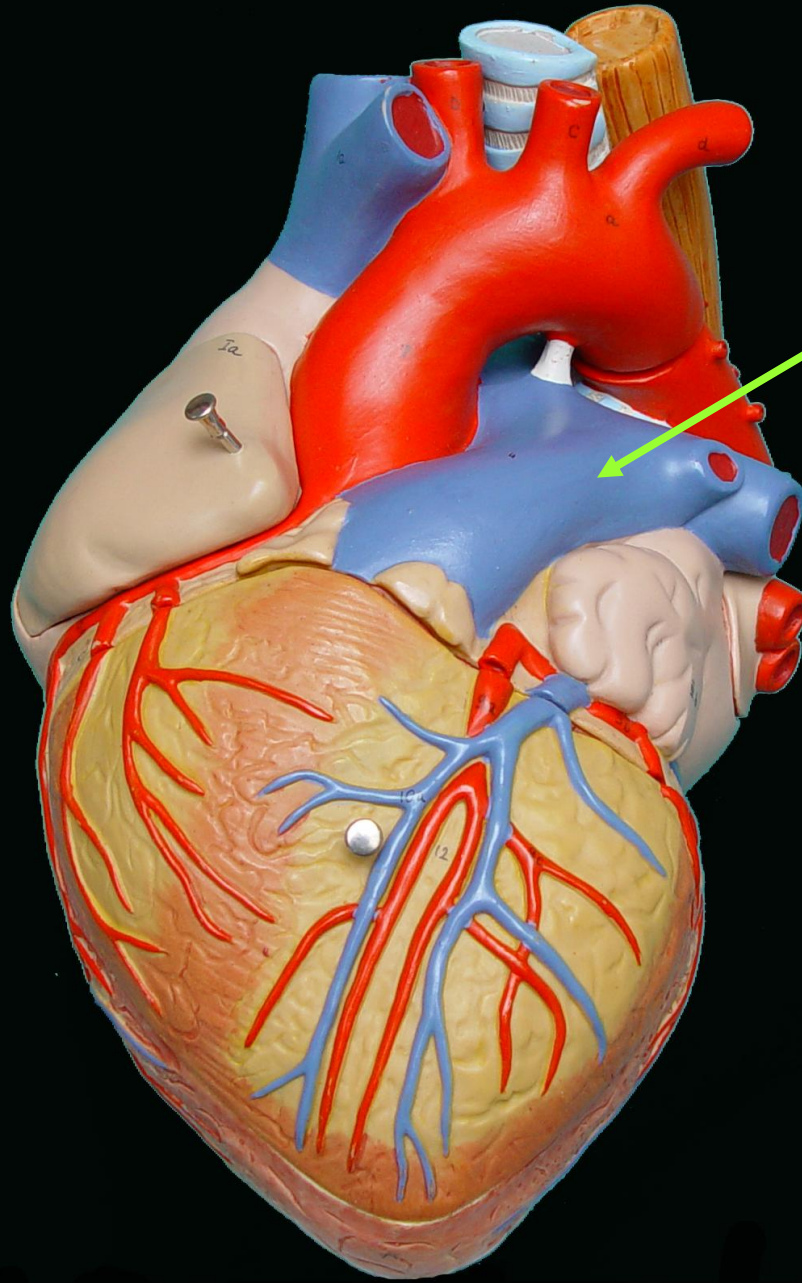


VENA
CAVA

SENO
CORONARIO

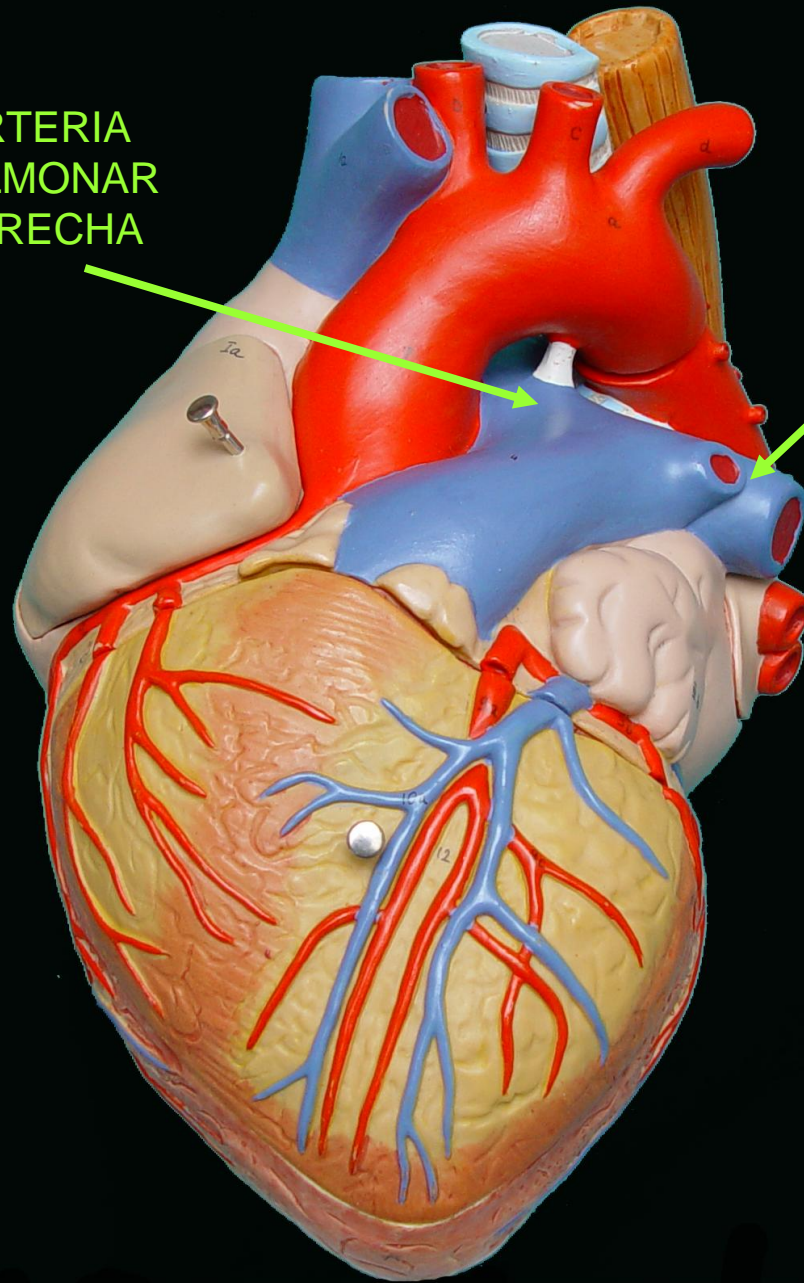


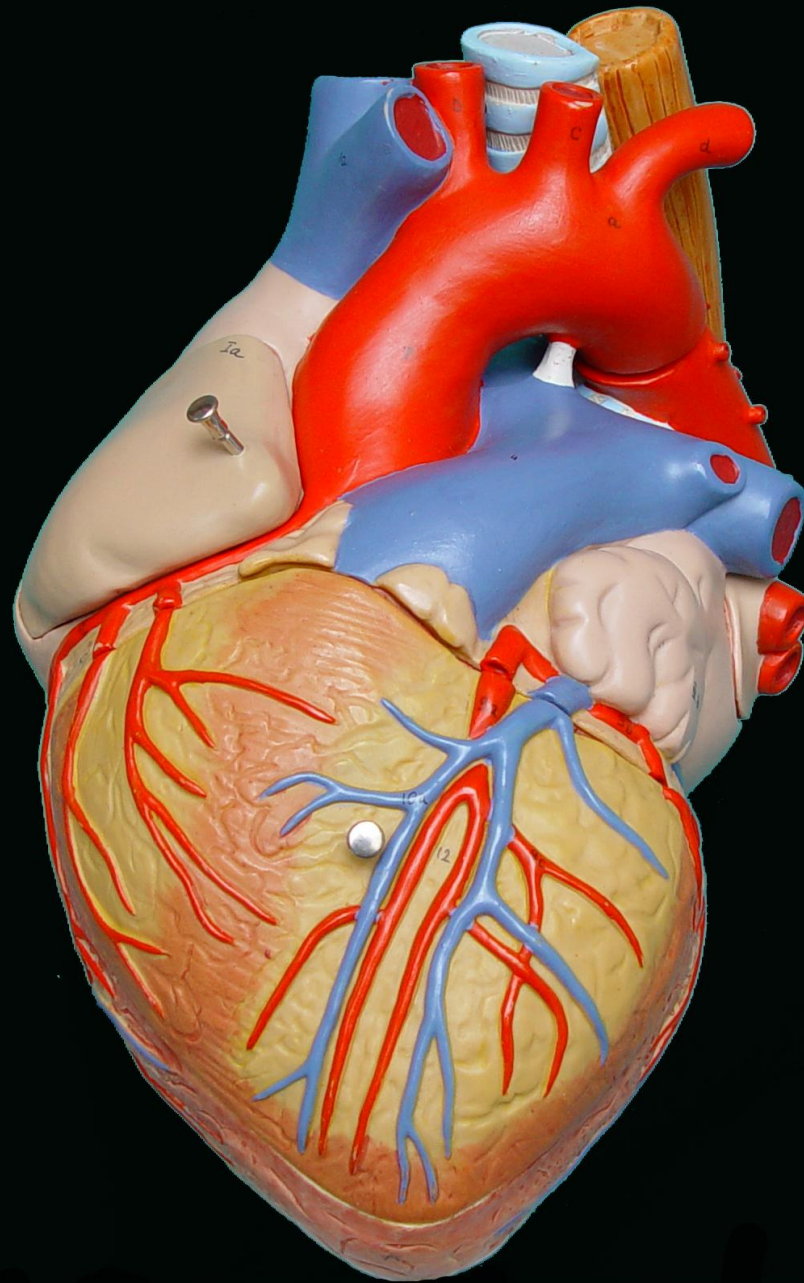
ARTERIA
PULMONAR




ARTERIA
PULMONAR
DERECHA

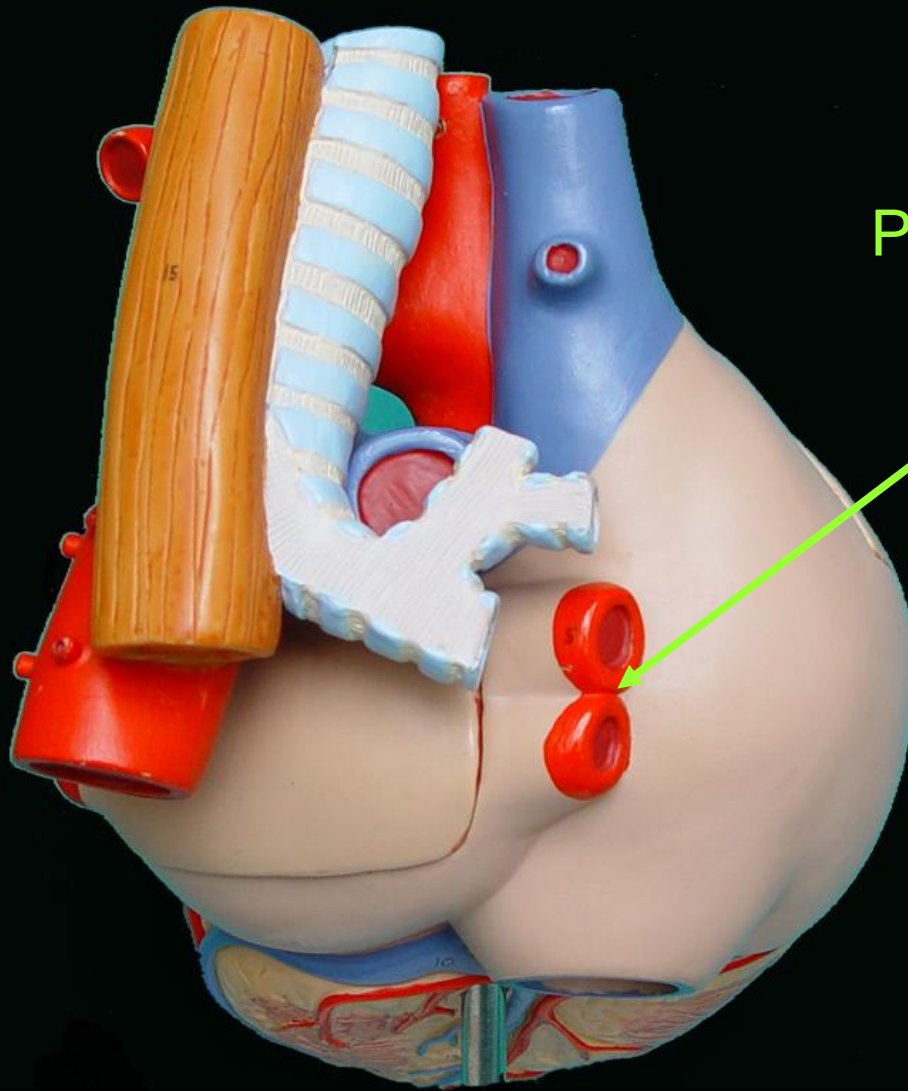
ARTERIA
PULMONAR
IZQUIERDA





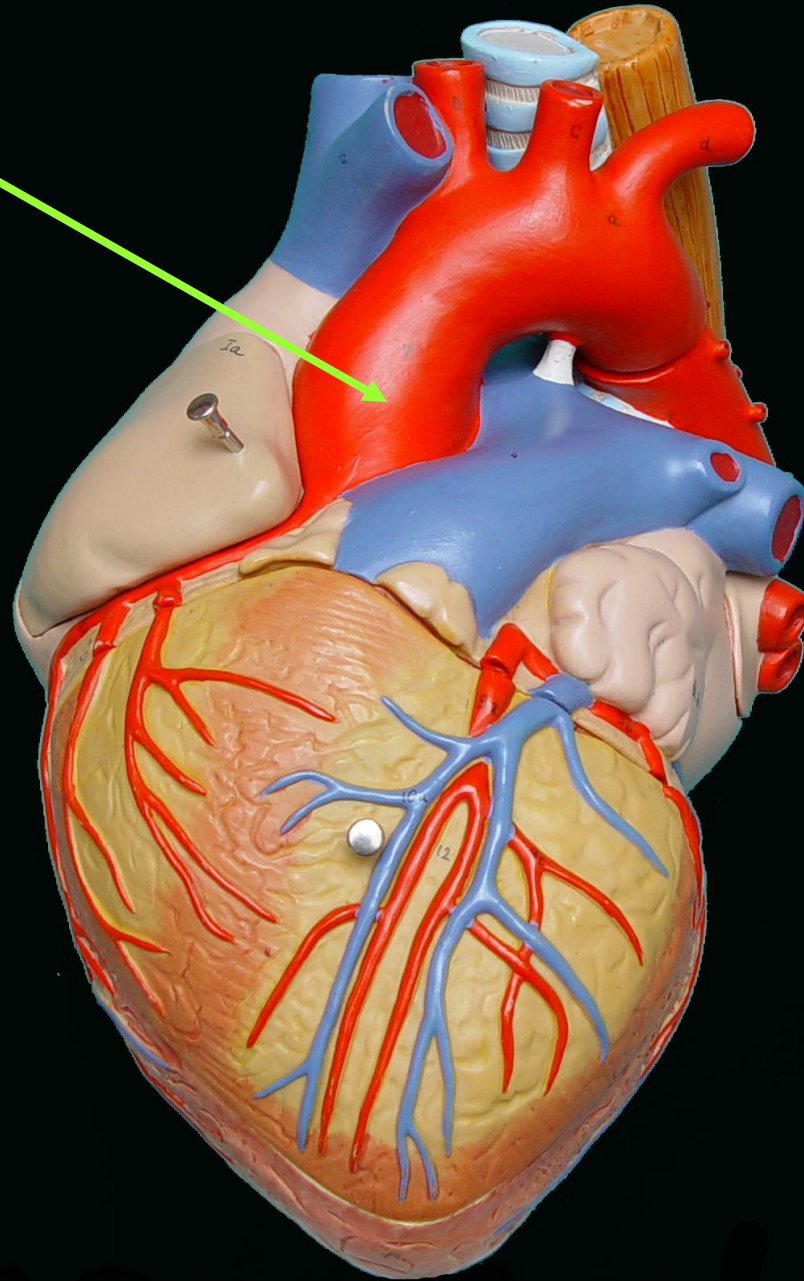
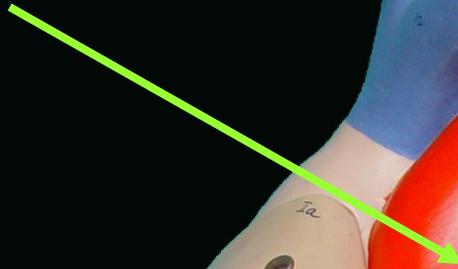
VENAS
PULMONARES
IZQUIERDAS

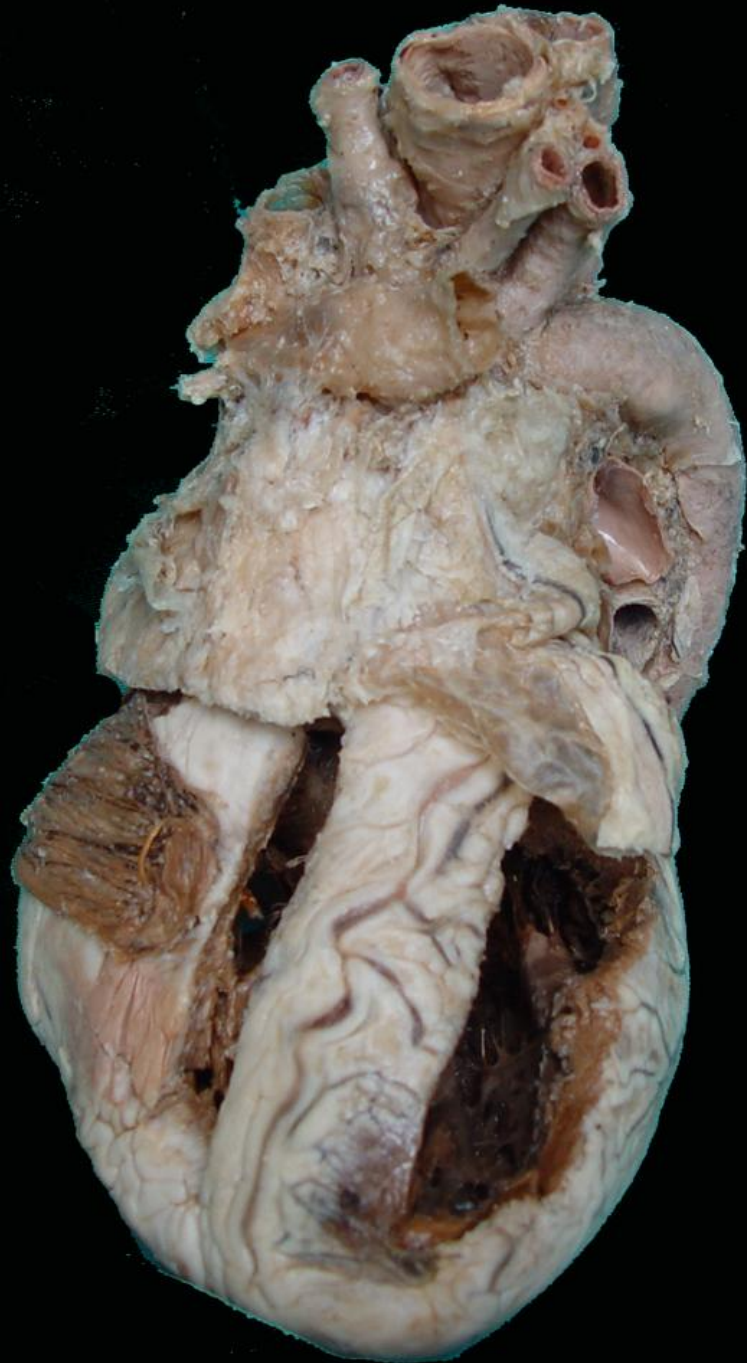



VENAS
PULMONARES
DERECHAS

AORTA

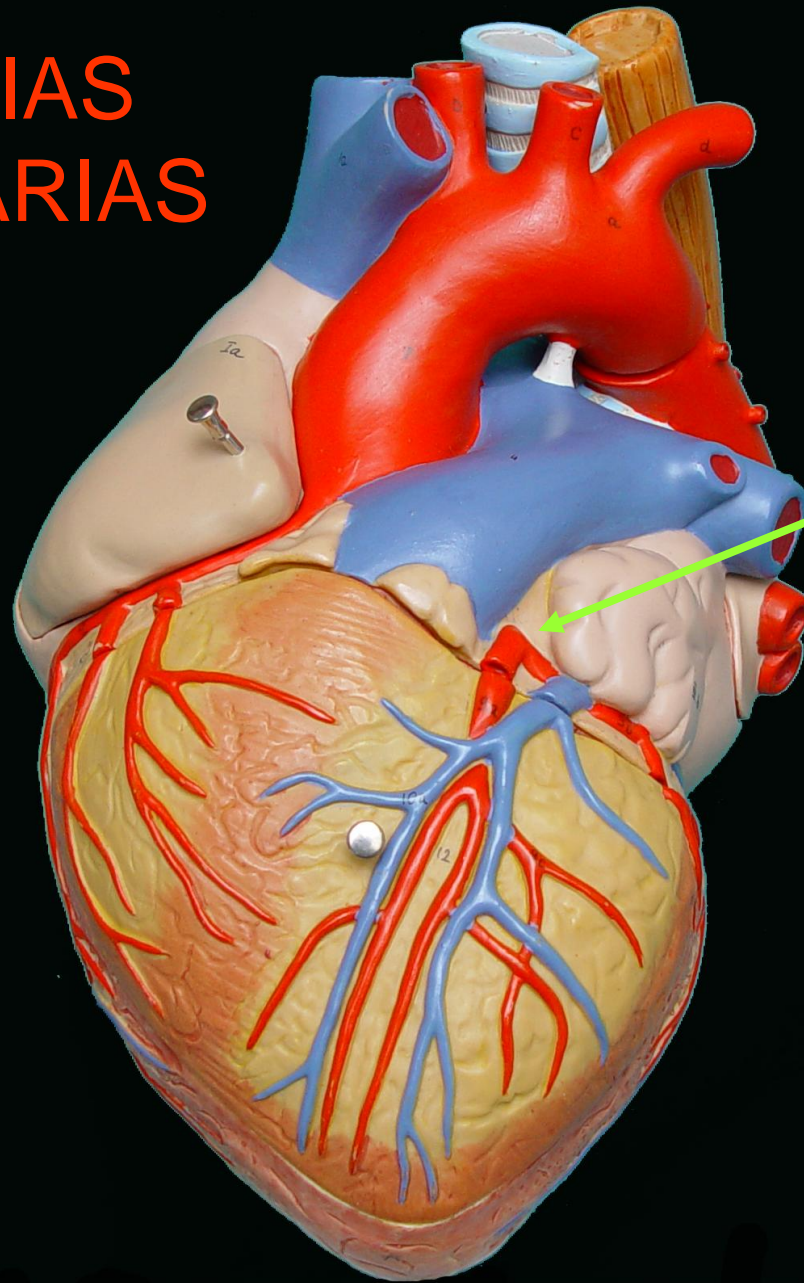




Corazón plastinado

VASOS CARDIACOS

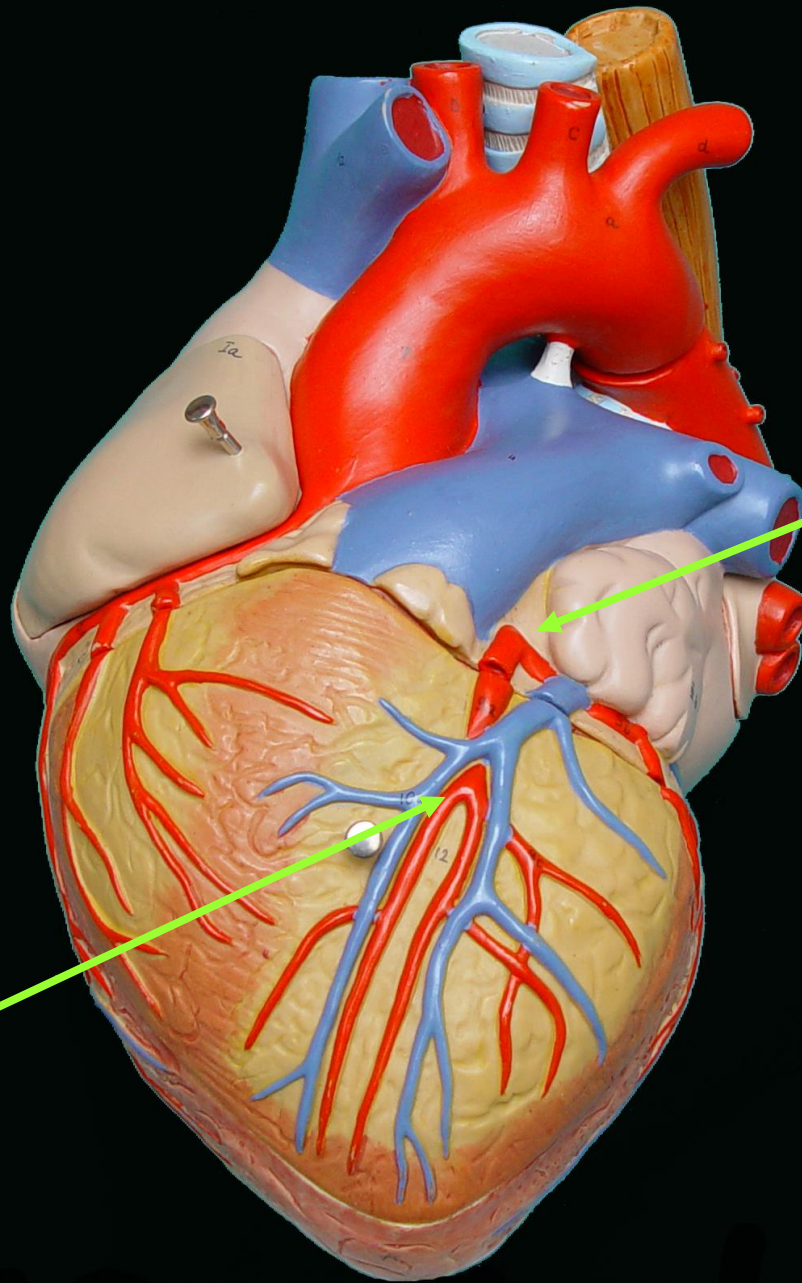
ARTERIAS CORONARIAS

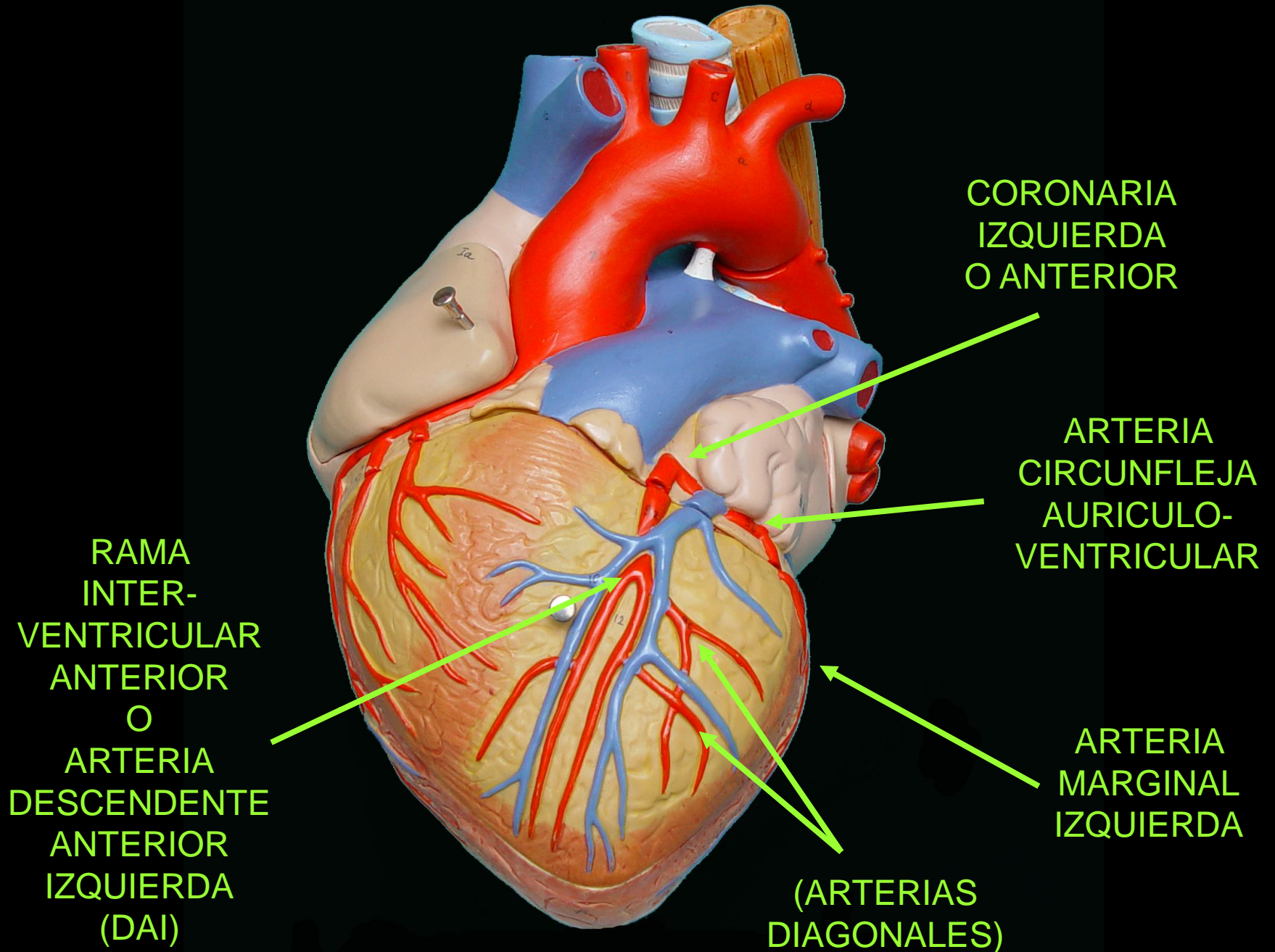


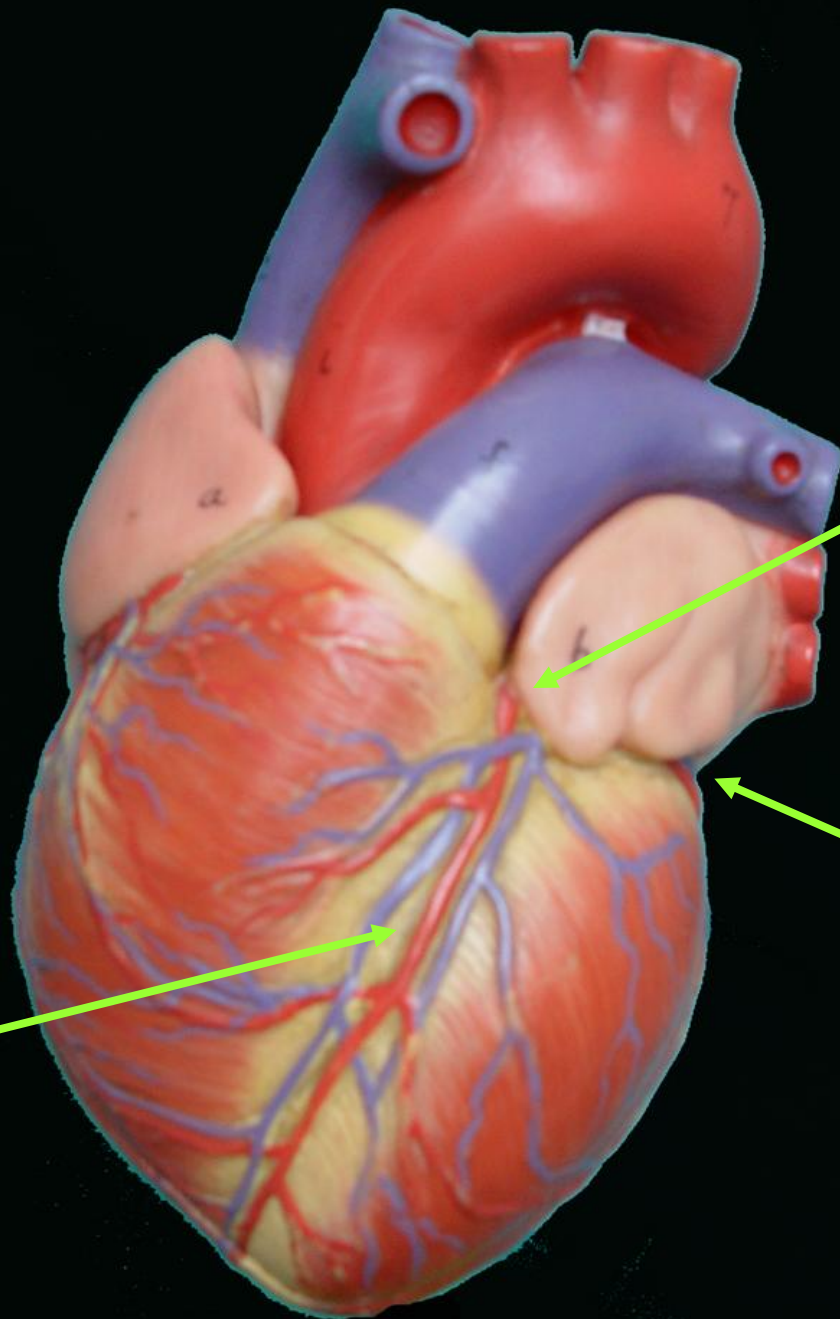
CORONARIA
IZQUIERDA
O ANTERIOR

CORONARIA
IZQUIERDA
O ANTERIOR

RAMA
INTER-
VENTRICULAR
ANTERIOR
O
ARTERIA
DESCENDENTE
ANTERIOR
IZQUIERDA
(DAI)







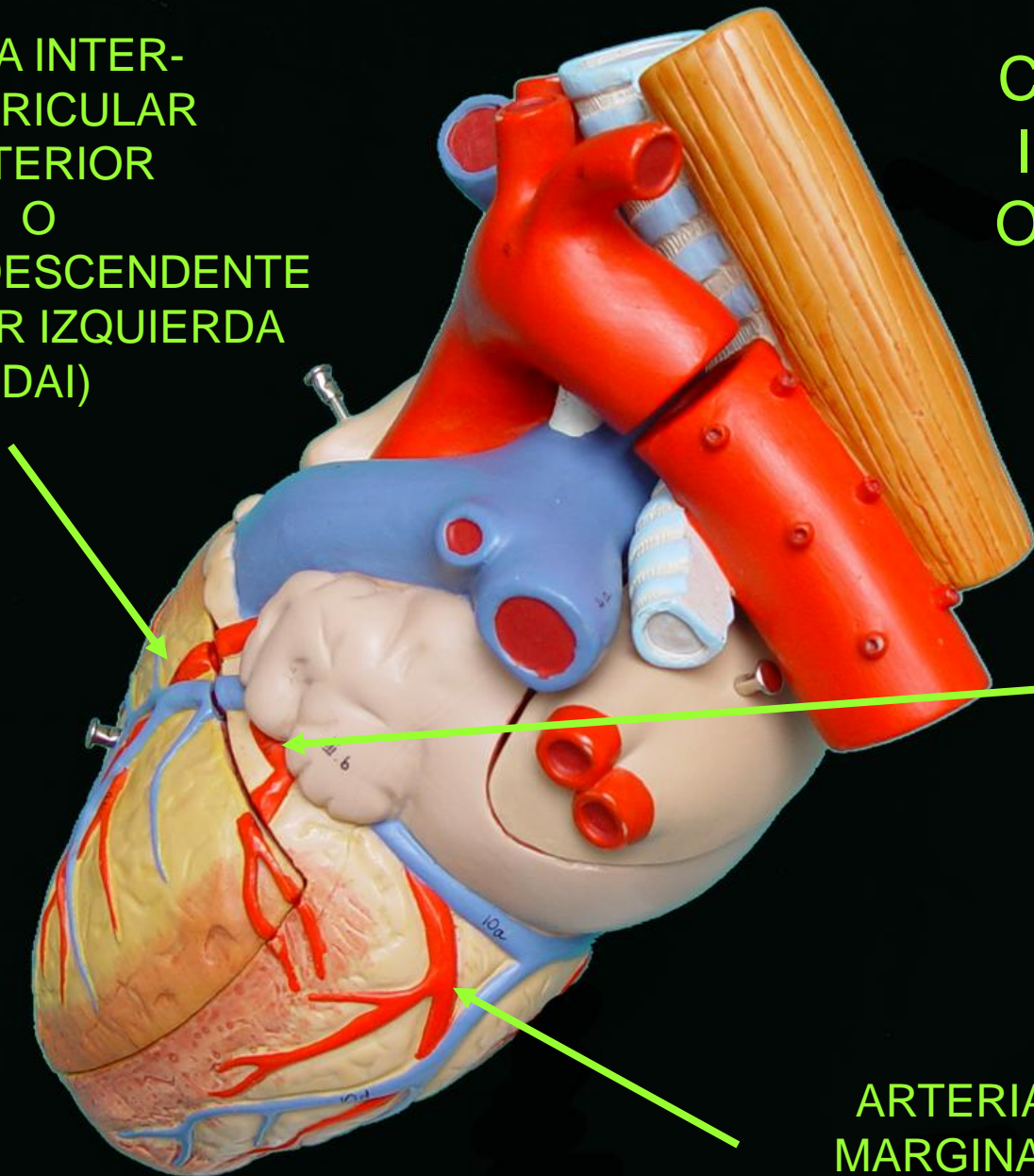
CORONARIA
IZQUIERDA
O ANTERIOR

RAMA
INTER-
VENTRICULAR
ANTERIOR
O
ARTERIA
DESCENDENTE
ANTERIOR
IZQUIERDA
(DAI)

ARTERIA
CIRCUNFLEJA
AURICULO-
VENTRICULAR

RAMA INTER-
VENTRICULAR
ANTERIOR
O
ARTERIA DESCENDENTE
ANTERIOR IZQUIERDA
(DAI)

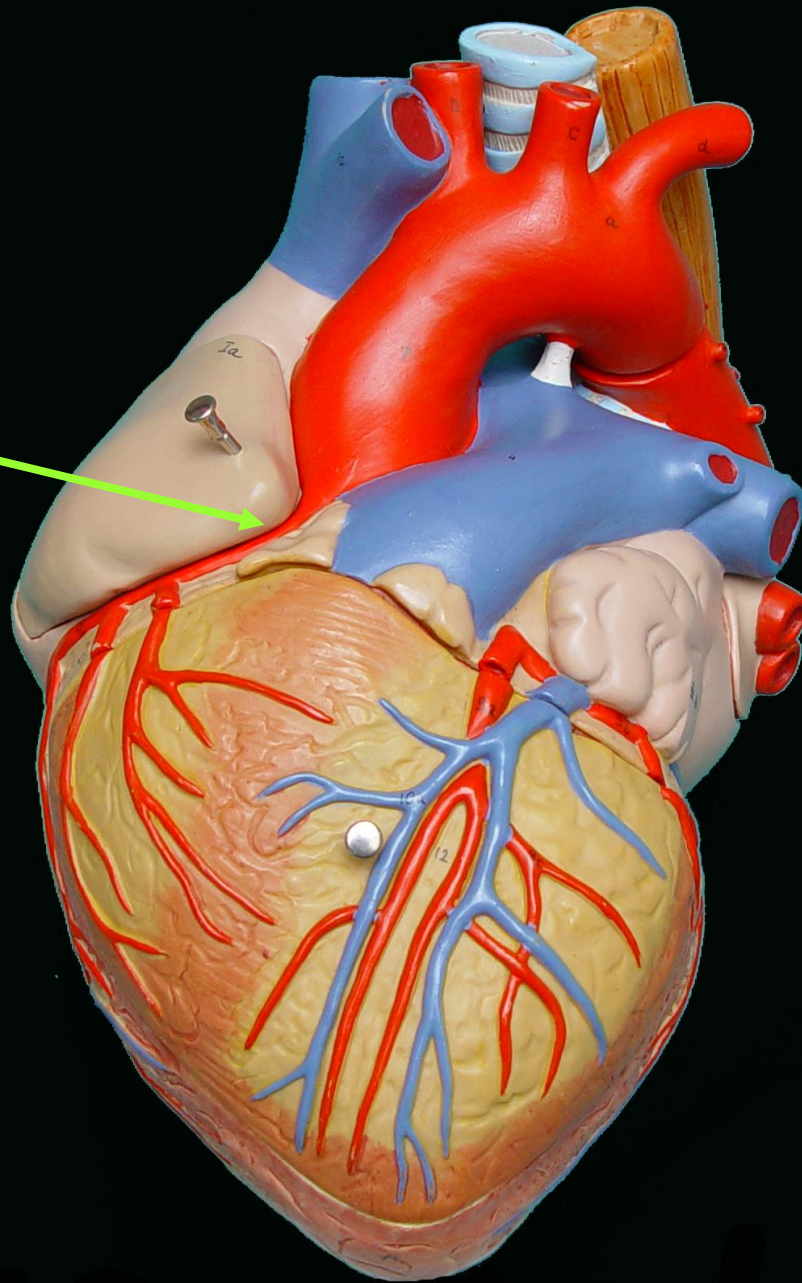
CORONARIA
IZQUIERDA
O ANTERIOR



ARTERIA
CIRCUNFLEJA
AURICULO-
VENTRICULAR

ARTERIA
MARGINAL
IZQUIERDA

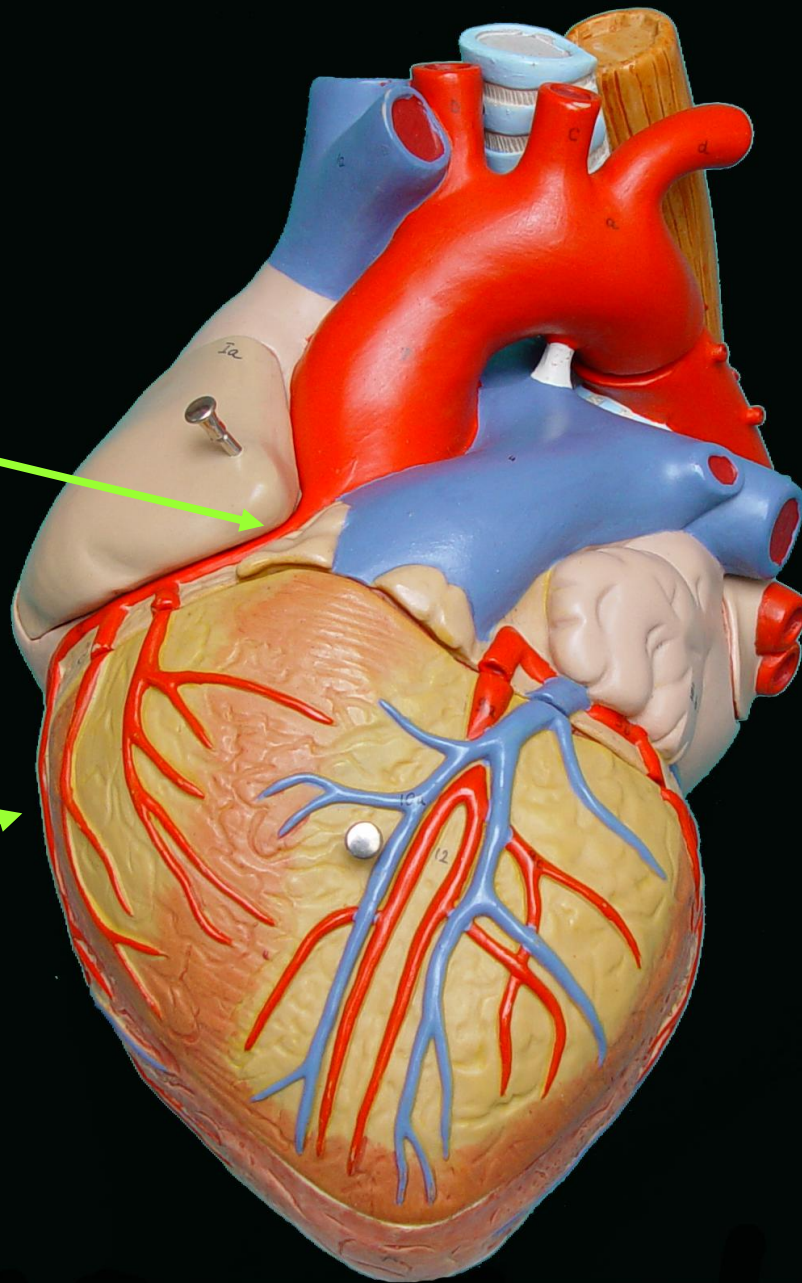
CORONARIA
DERECHA O
POSTERIOR

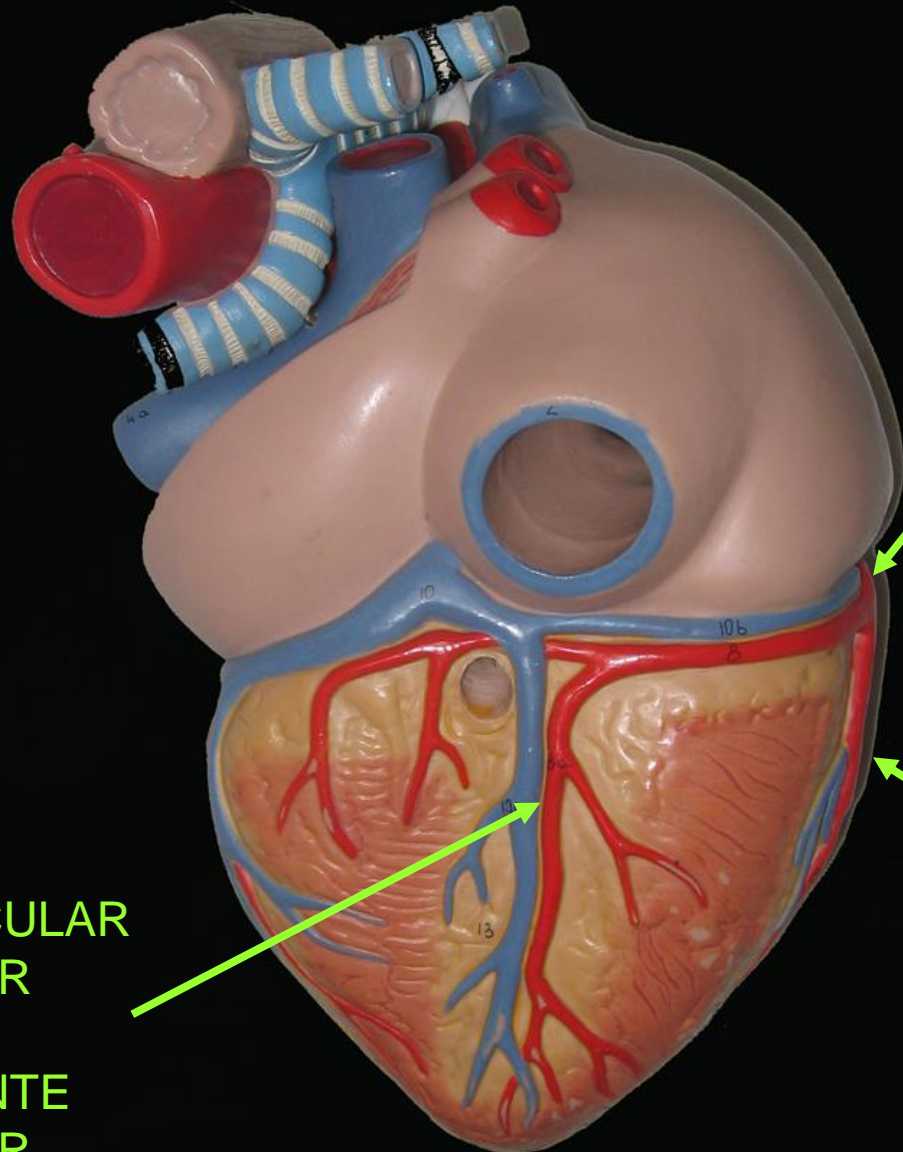


CORONARIA
DERECHA O
POSTERIOR



ARTERIA
MARGINAL
DERECHA

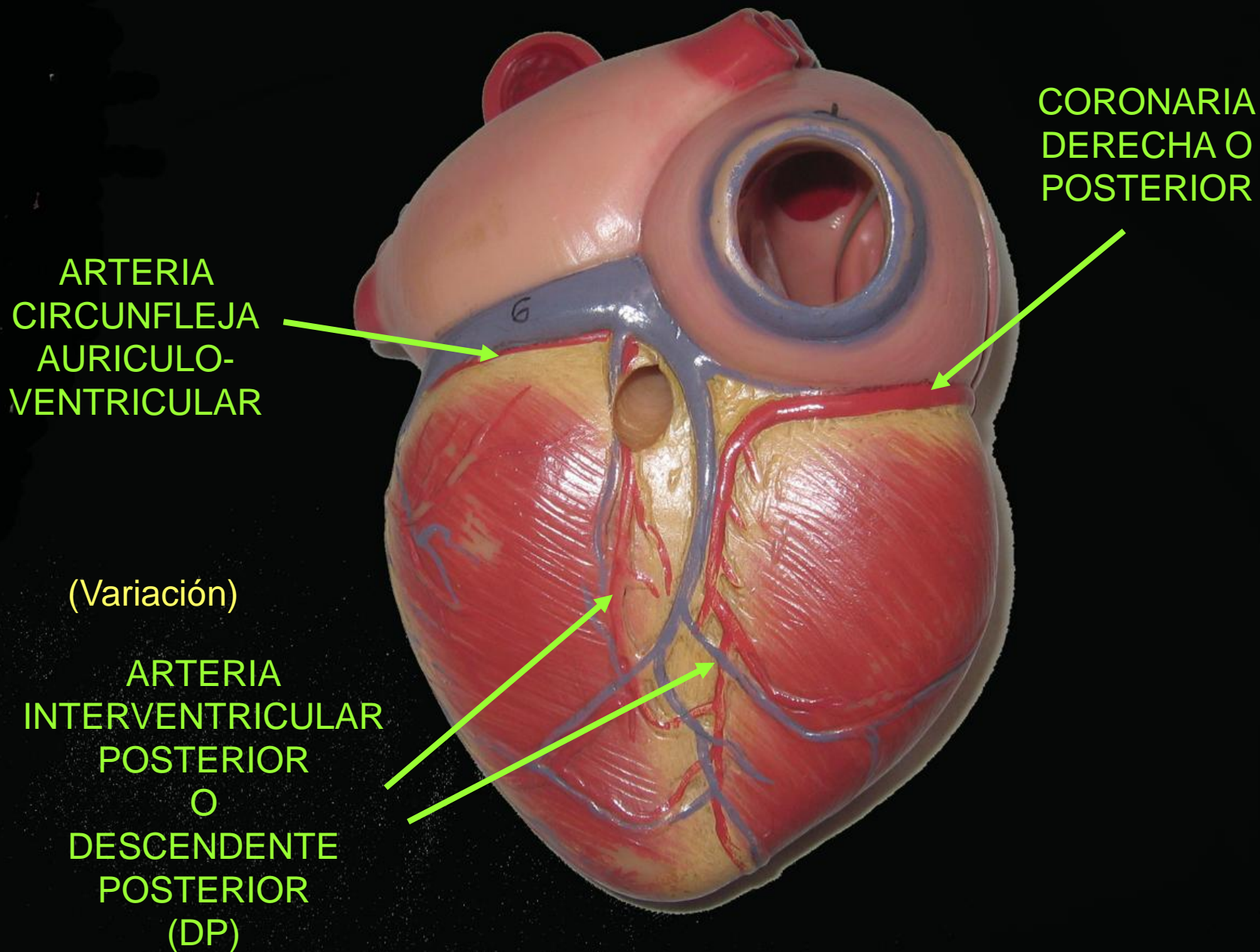




CORONARIA
DERECHA O
POSTERIOR

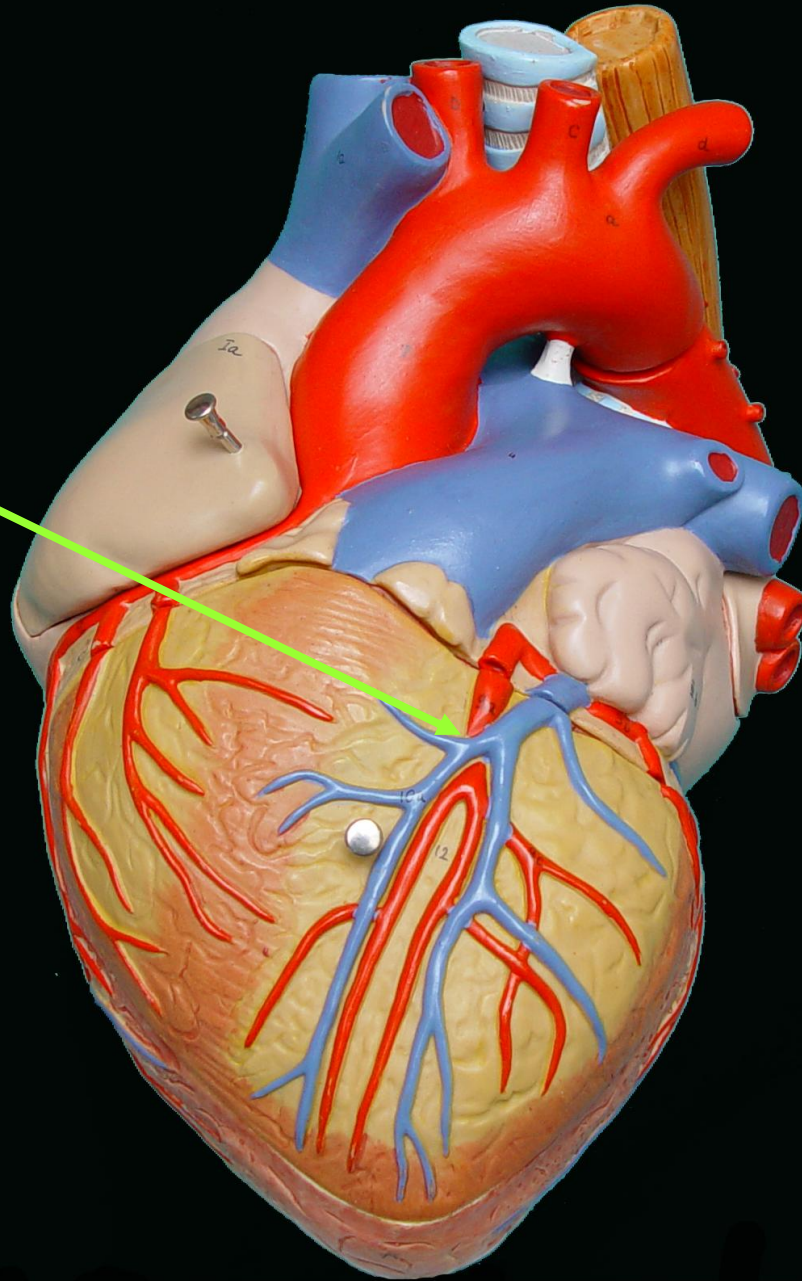
ARTERIA
INTERVENTRICULAR
POSTERIOR
O
DESCENDENTE
POSTERIOR
(DP)

ARTERIA
MARGINAL
DERECHA



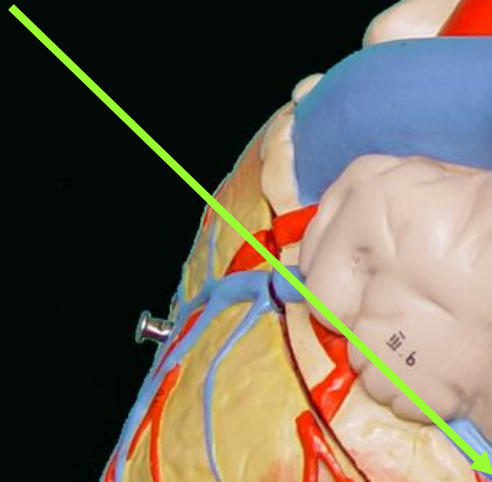
VENAS CARDIACAS

VENA
CORONARIA
MAYOR
O
INTER-
VENTRICULAR
ANTERIOR

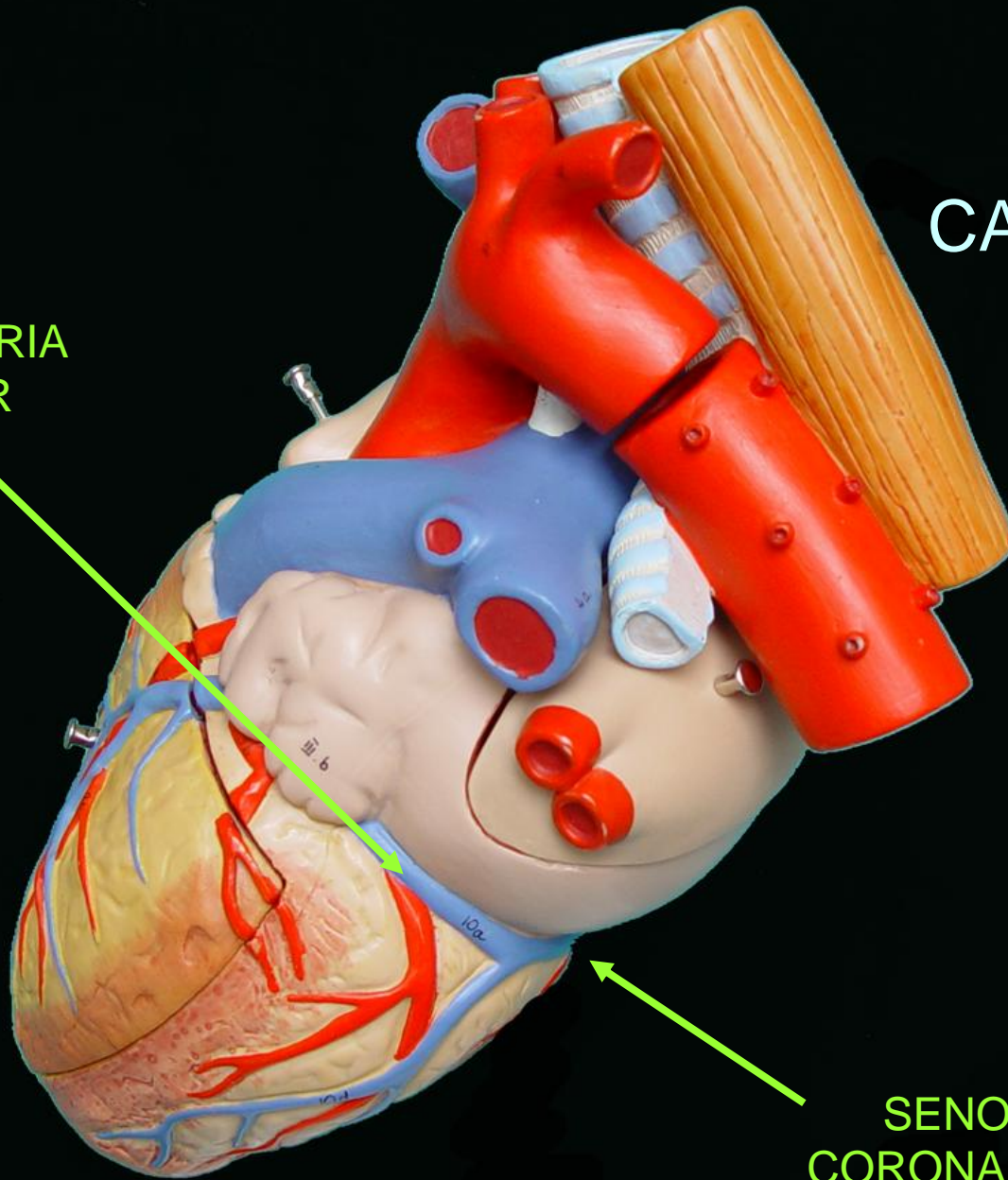



VENAS CARDIACAS

VENA
CORONARIA
MAYOR

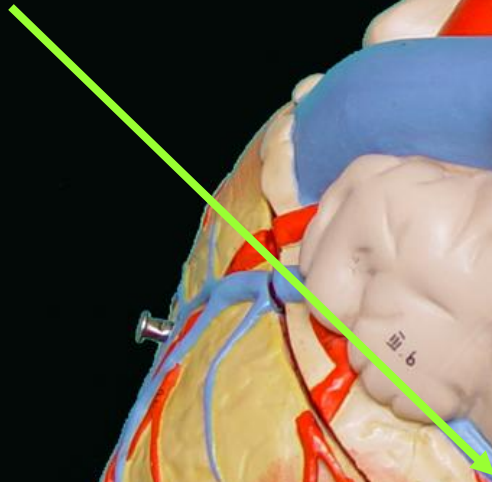


SENO
CORONARIO



VENAS CARDIACAS

VENA
CORONARIA
MAYOR

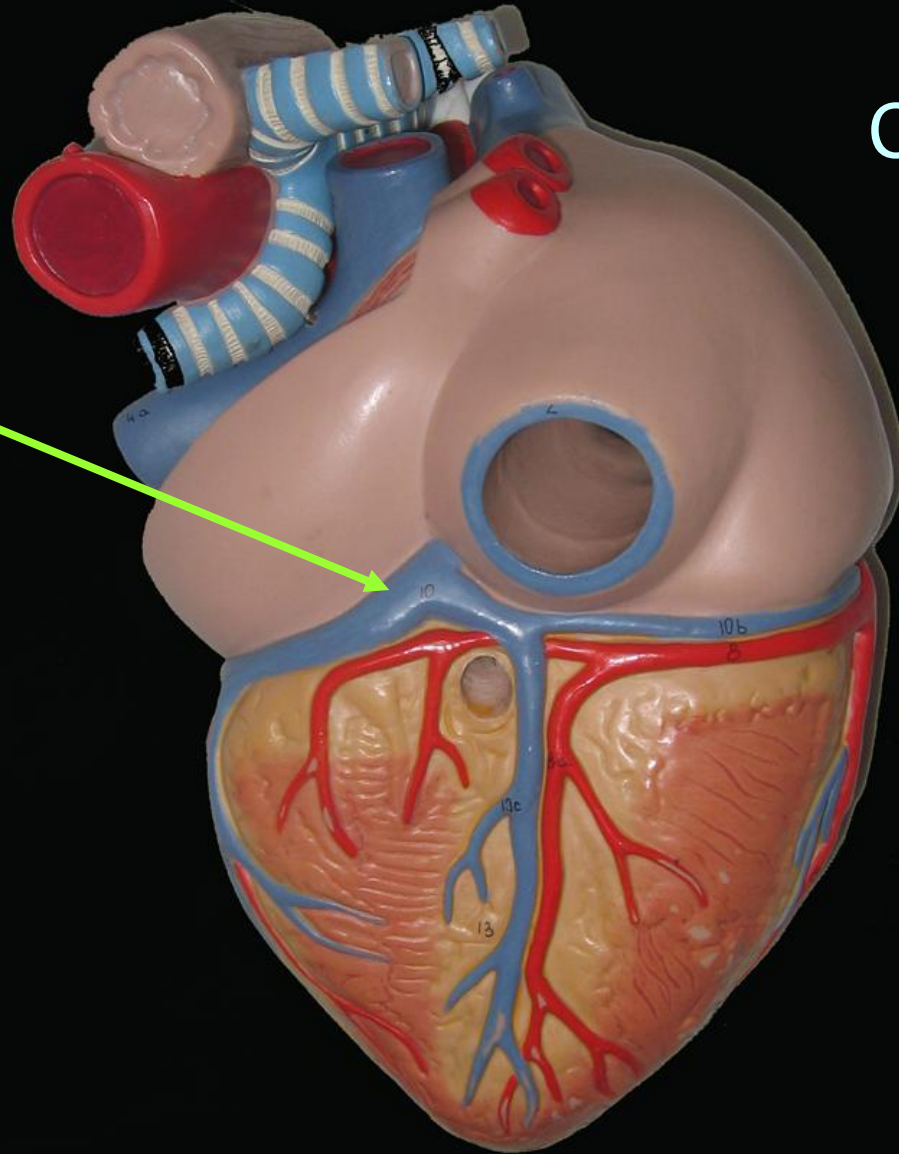
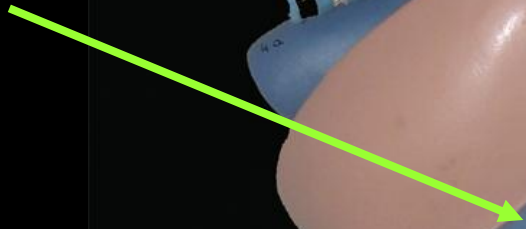


SENO
CORONARIO

VENA POSTERIOR DEL
VENTRÍCULO IZQUIERDO

VENAS CARDIACAS

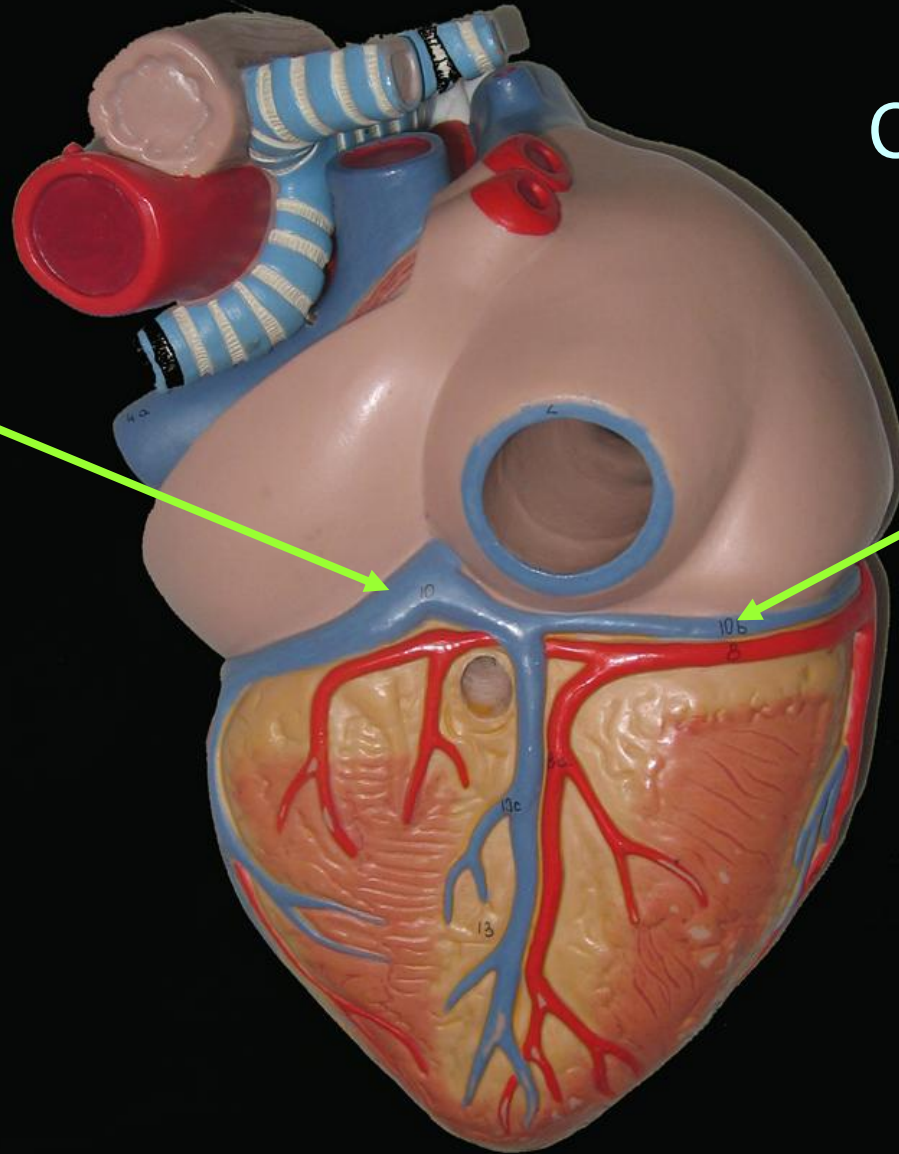
SENO
CORONARIO



VENAS CARDIACAS

SENO
CORONARIO

VENA
CORONARIA
MENOR
O
DERECHA

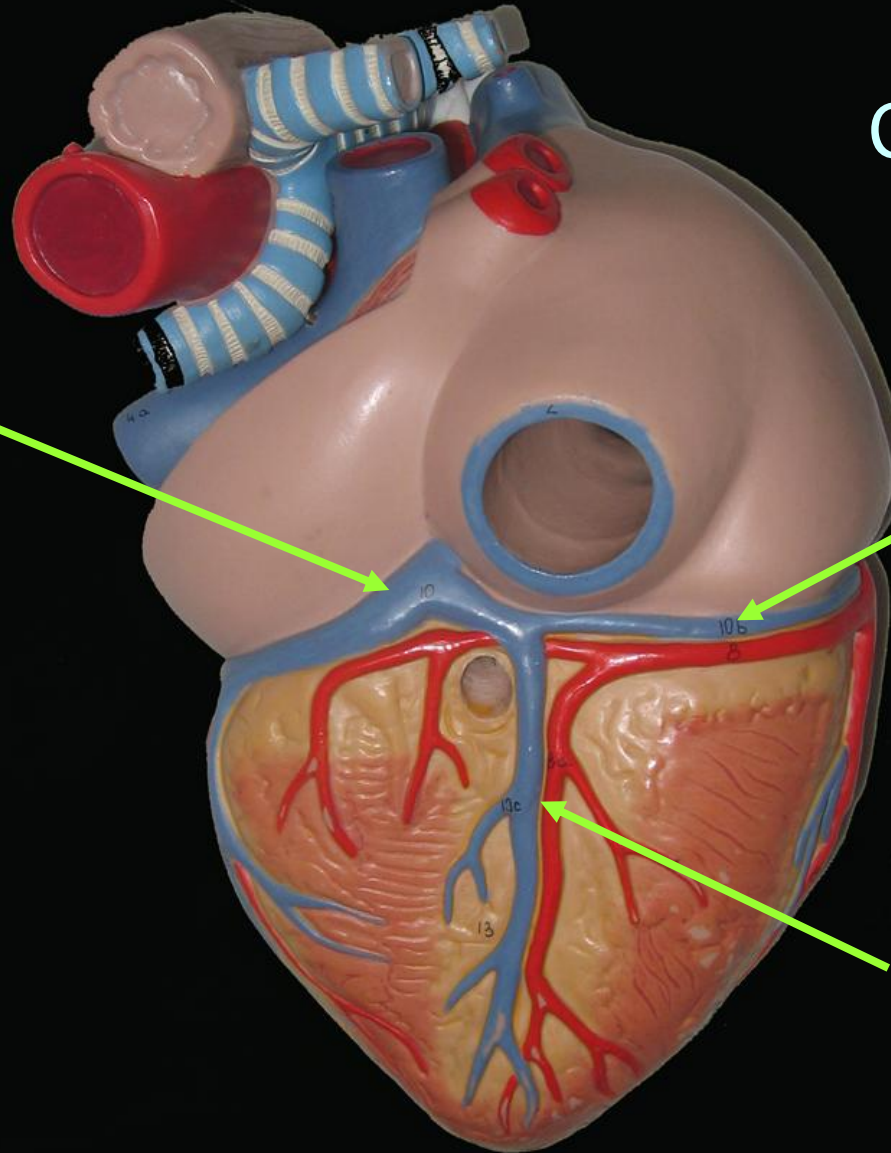


VENAS CARDIACAS

SENO
CORONARIO

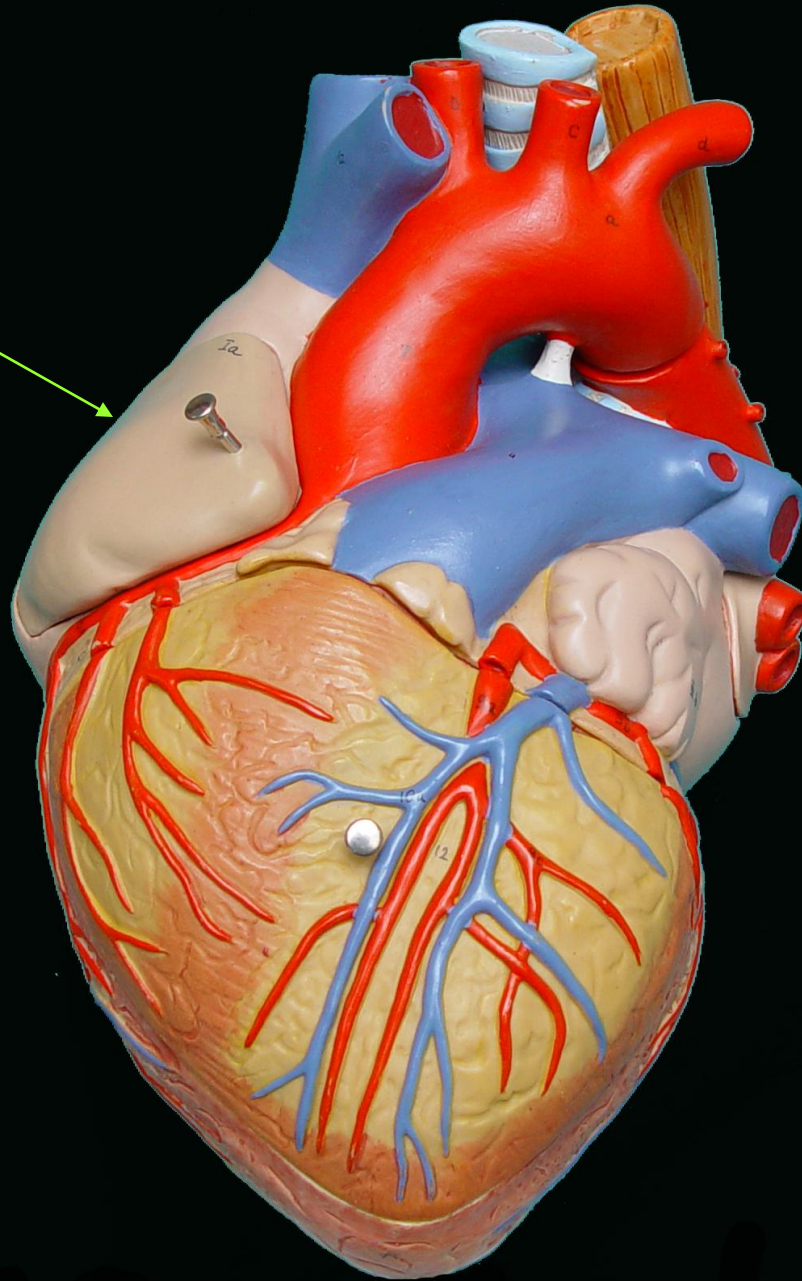

VENA
CORONARIA
MENOR
O
DERECHA

VENA
INTER-
VENTRICULAR
INFERIOR O
CORONARIA
MEDIA



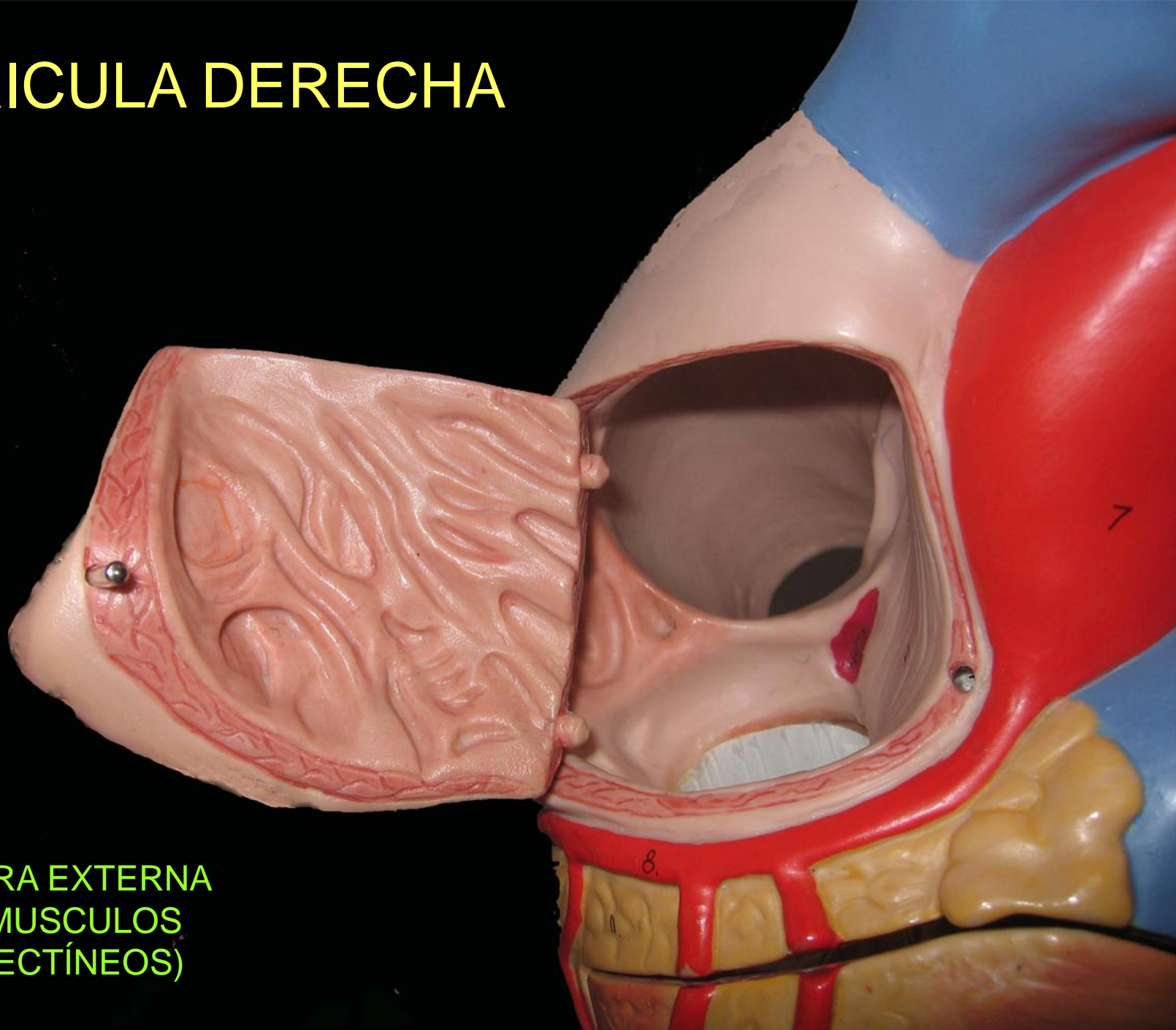
CAVIDADES CARDIACAS

AURICULA
DERECHA



AURICULA
DERECHA

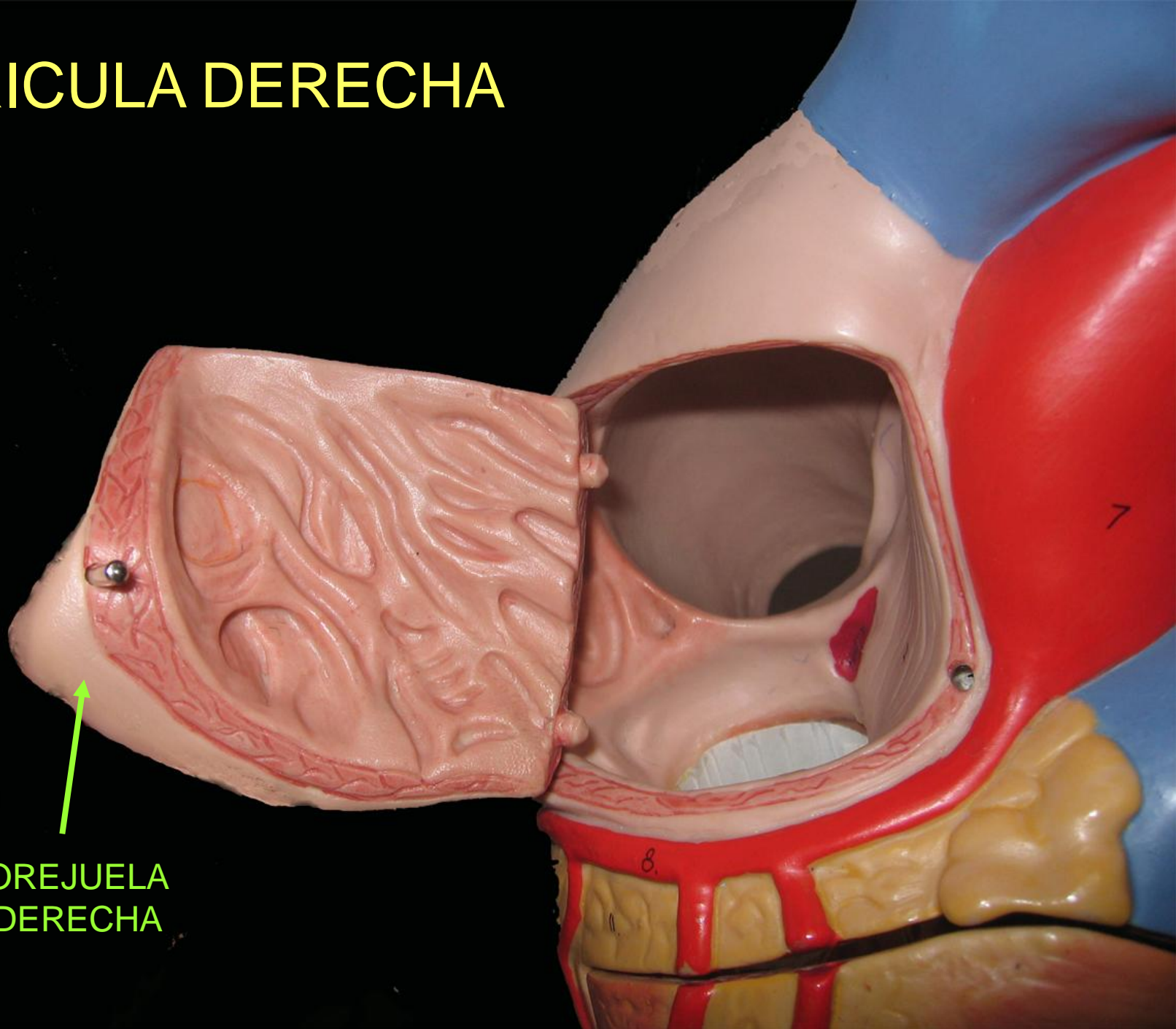
AURICULA DERECHA



CARA EXTERNA
(MUSCULOS
PECTÍNEOS)

AURICULA DERECHA

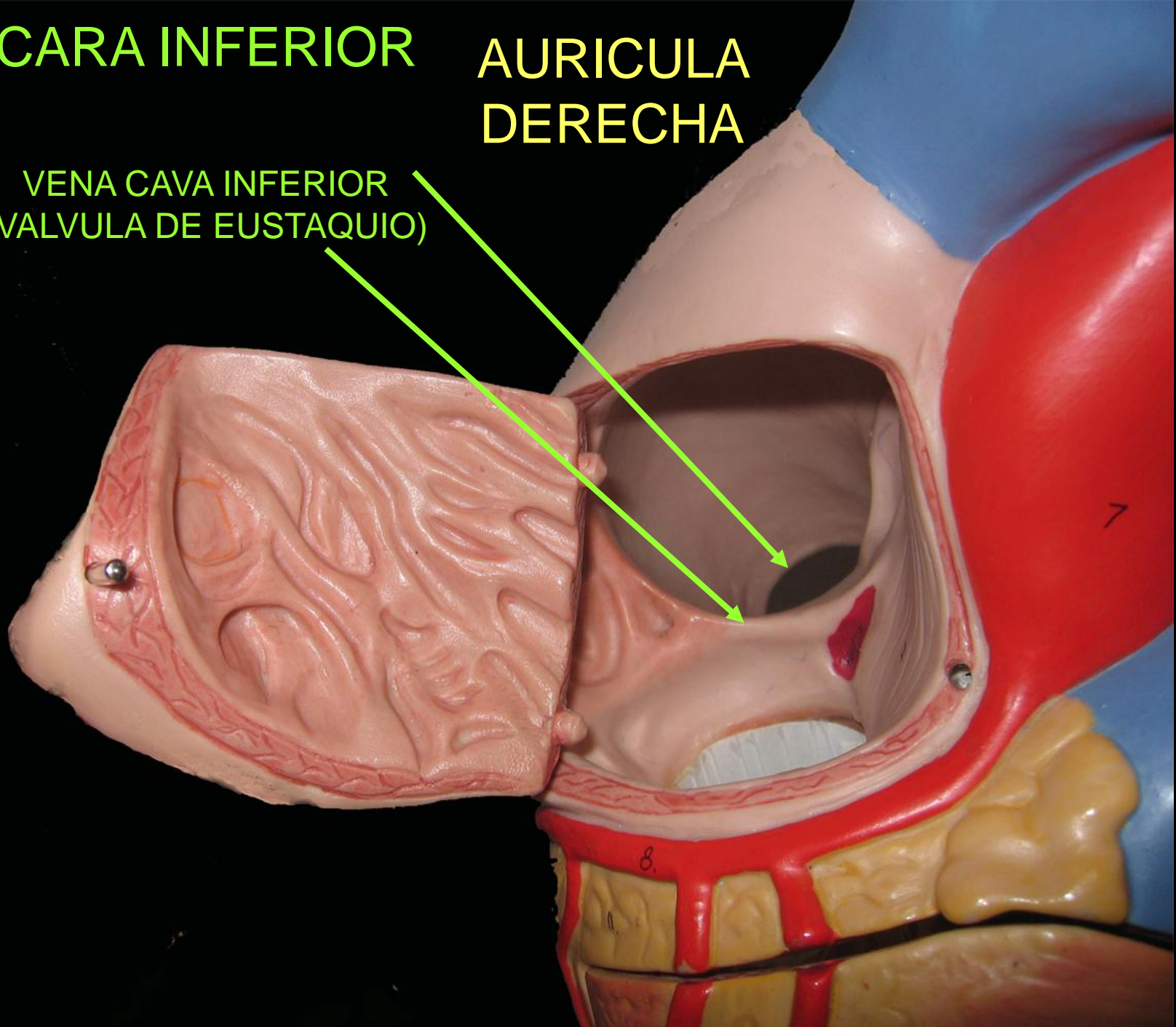
OREJUELA
DERECHA



CARA INFERIOR

AURICULA
DERECHA

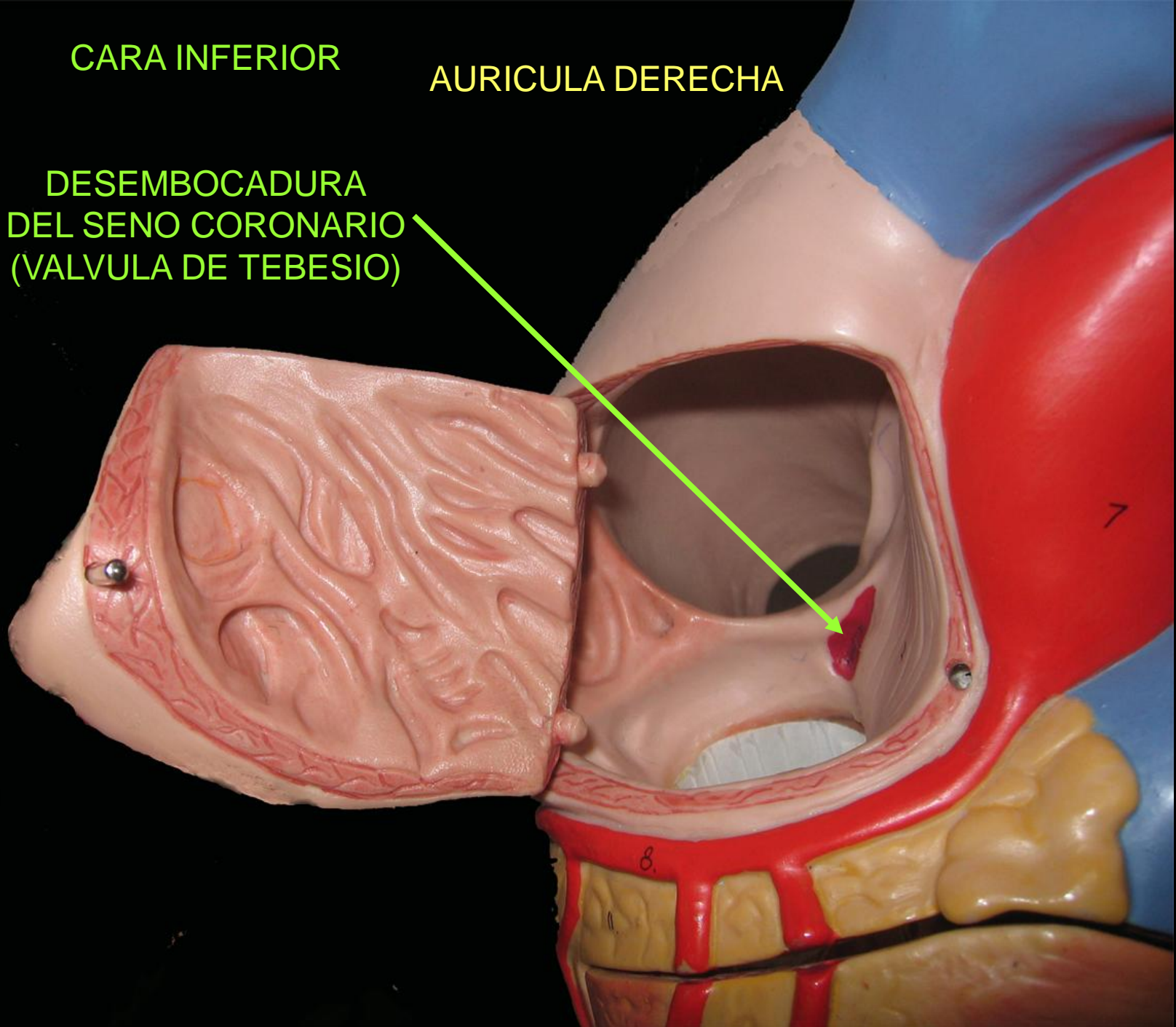
VENA CAVA INFERIOR
(VALVULA DE EUSTAQUIO)



CARA INFERIOR

AURICULA DERECHA

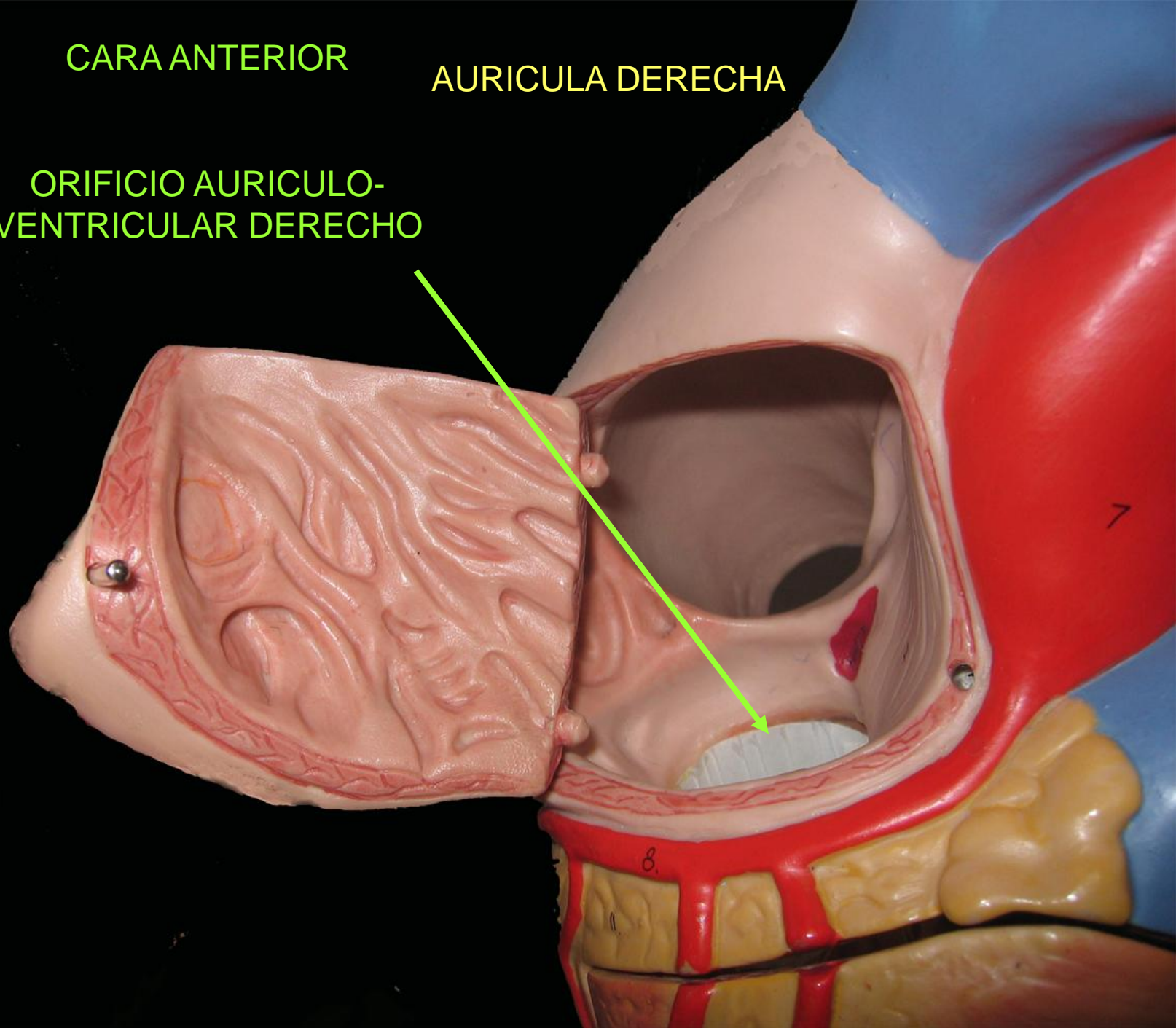
DESEMBOCADURA
DEL SENO CORONARIO
(VALVULA DE TEBESIO)



CARA ANTERIOR

AURICULA DERECHA

ORIFICIO AURICULO-
VENTRICULAR DERECHO

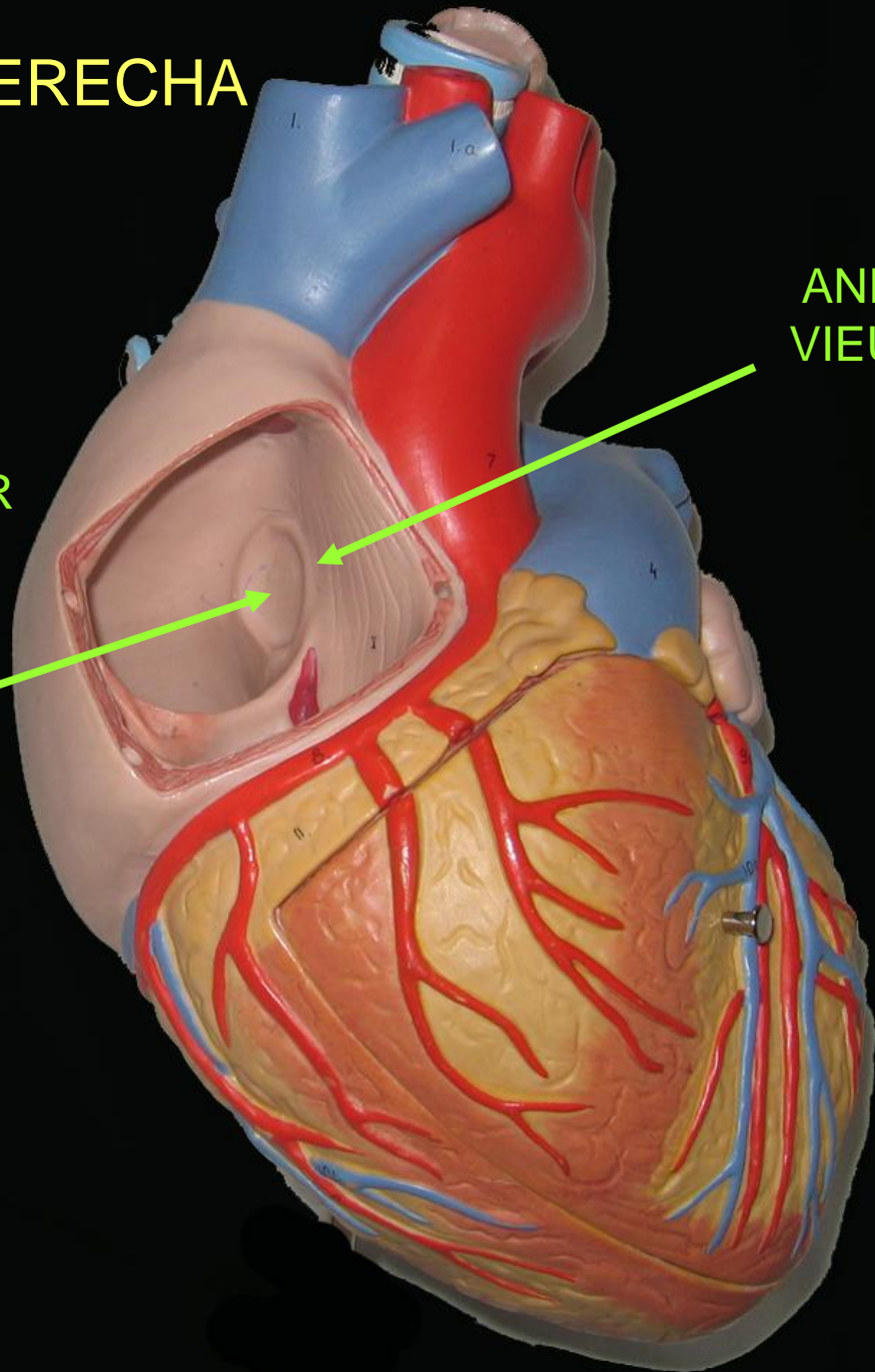


AURICULA DERECHA

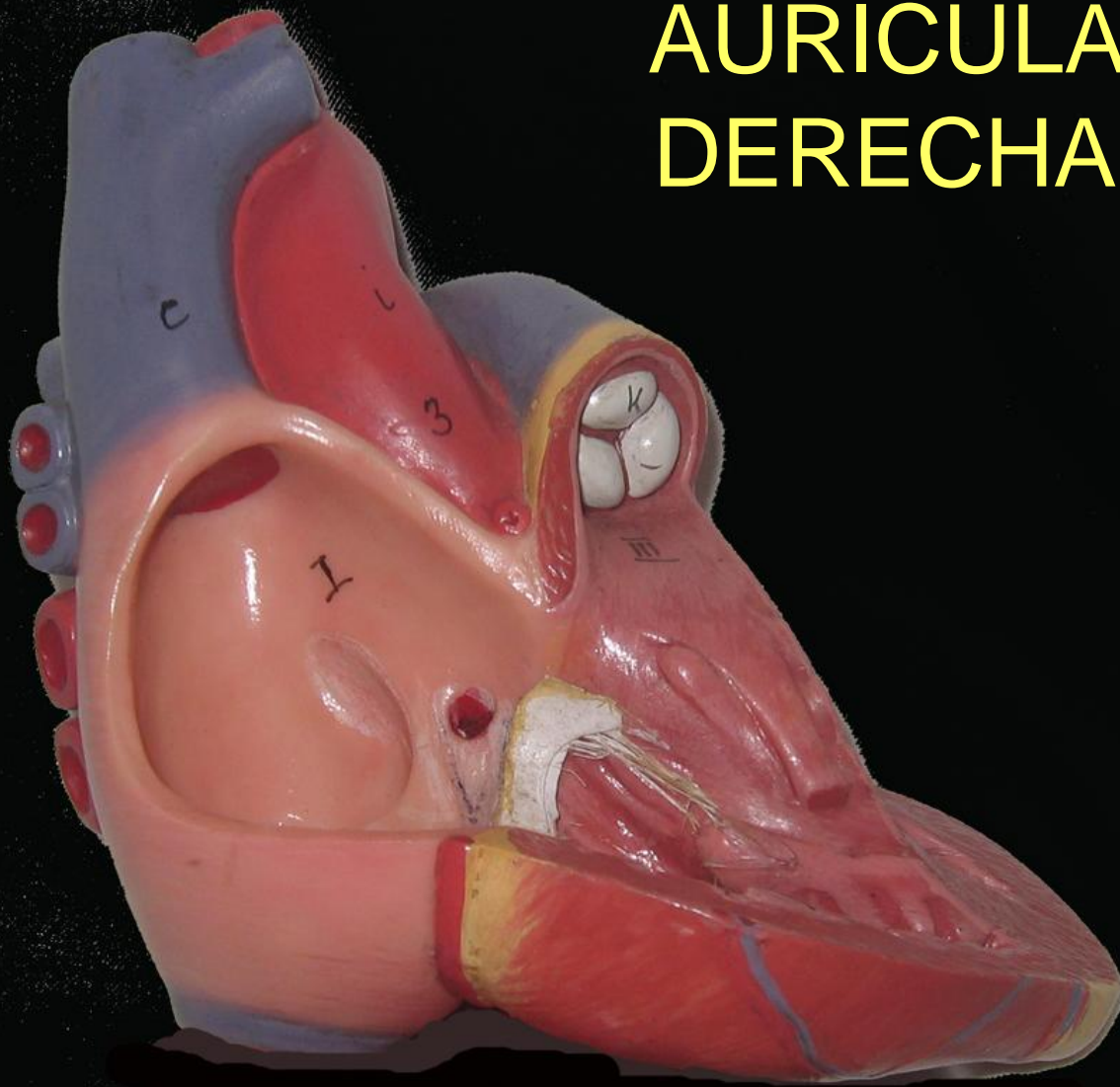
CARA INTERNA
O TABIQUE
INTERAURICULAR

FOSA
OVAL

ANILLO DE
VIEUSSENS



AURICULA DERECHA

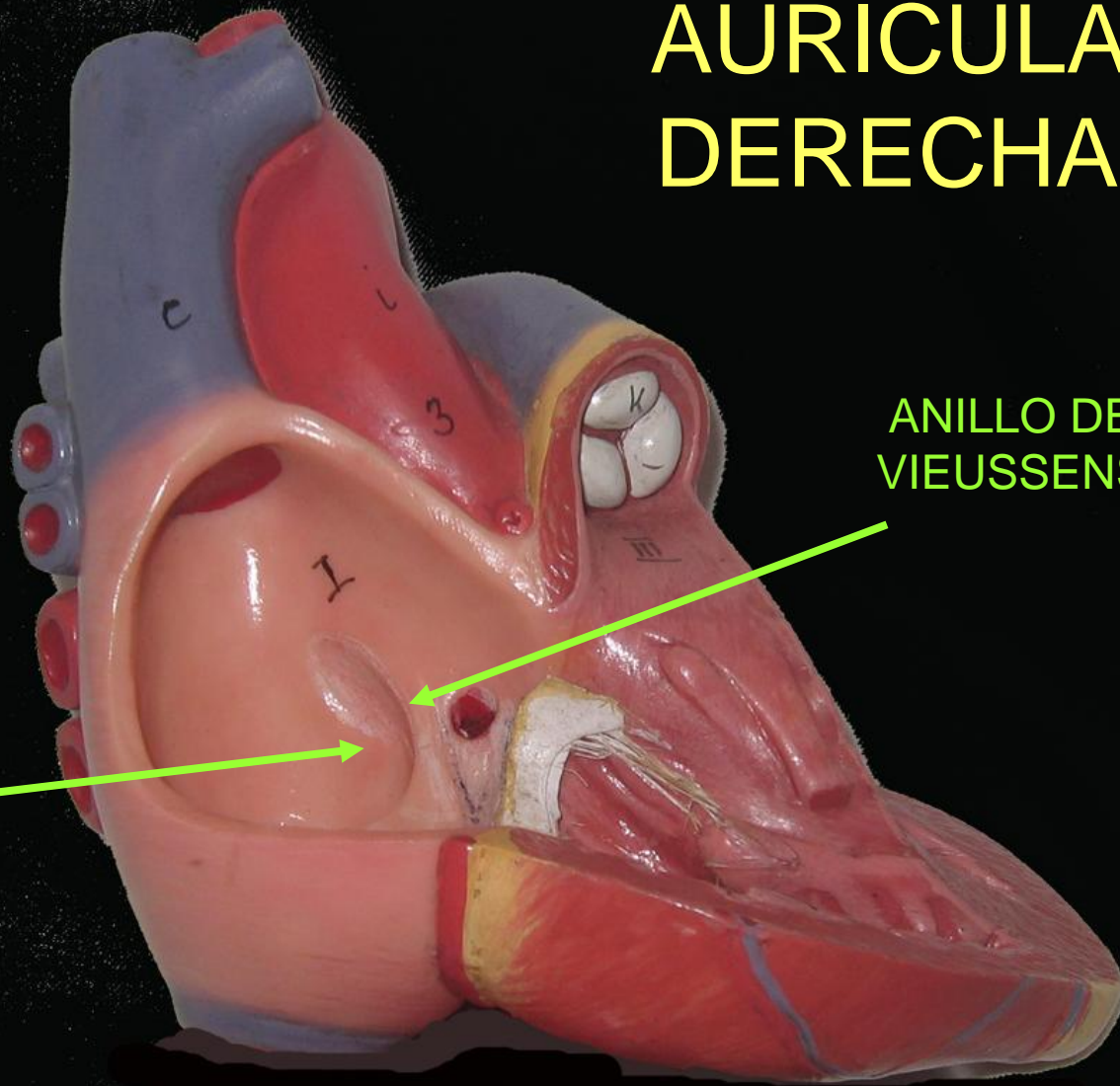


AURICULA DERECHA

FOSA OVAL

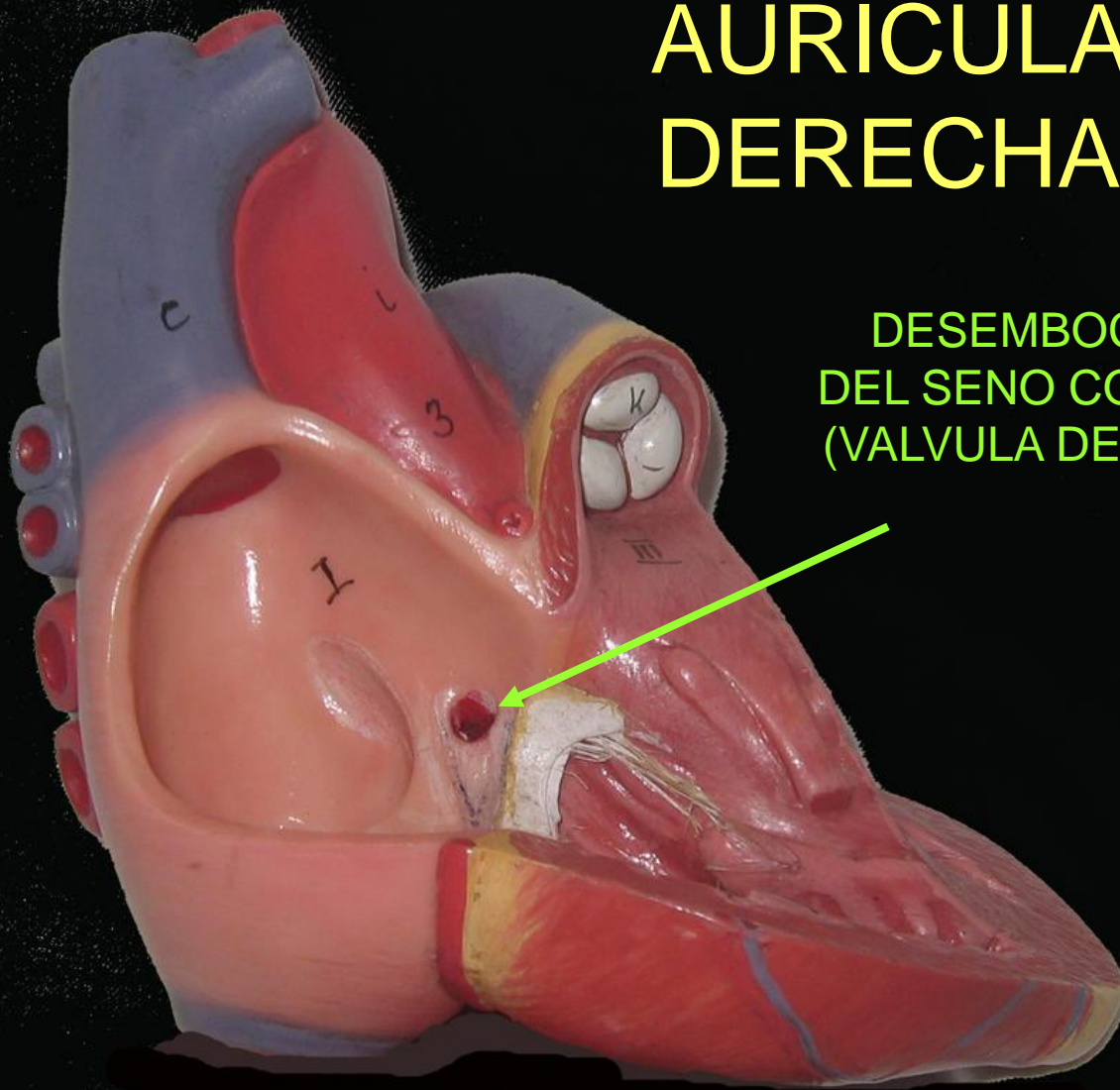
ANILLO DE VIEUSSENS

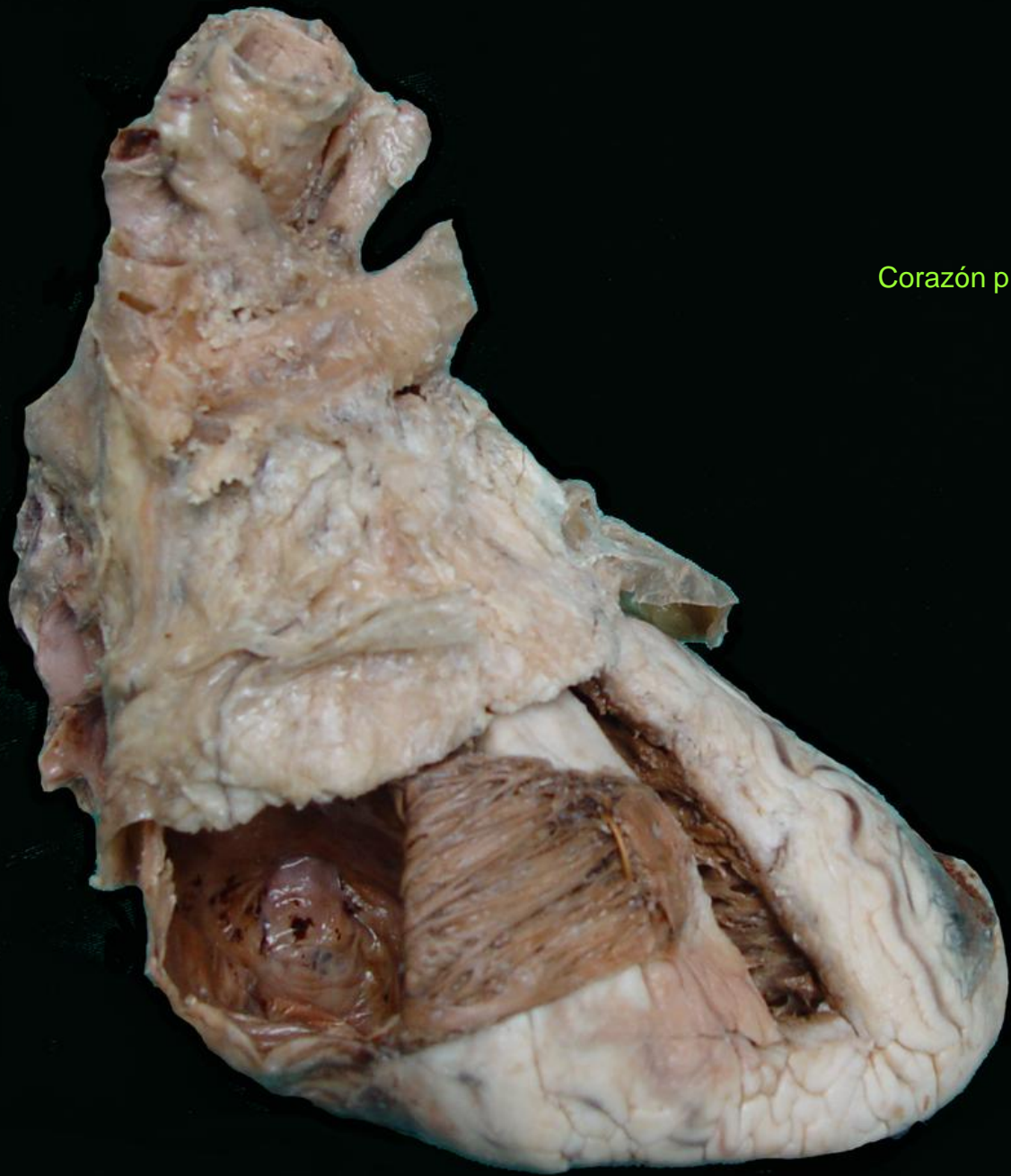
CARA INTERNA O TABIQUE INTERAURICULAR



AURICULA DERECHA

DESEMBOCADURA
DEL SENO CORONARIO
(VALVULA DE TEBESIO)

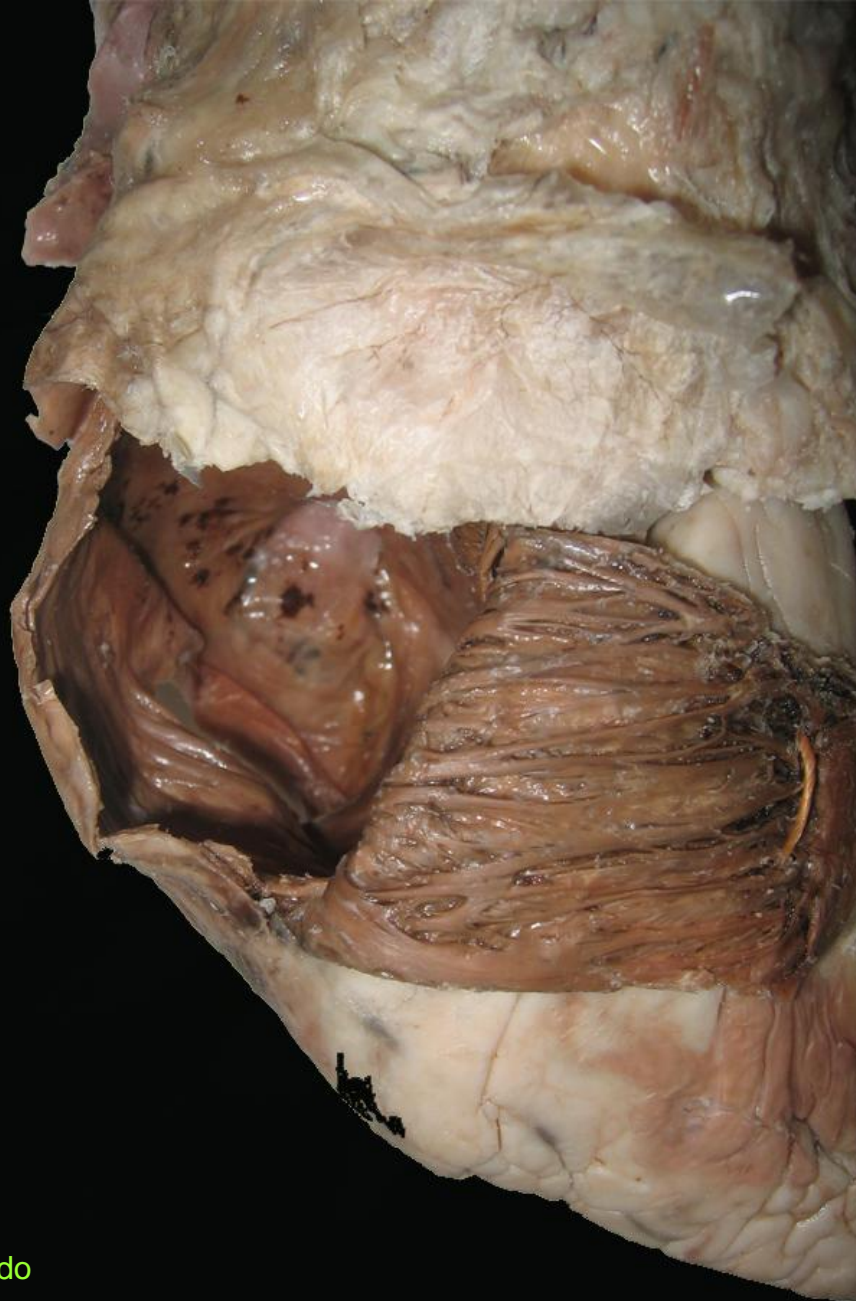




Corazón plastinado

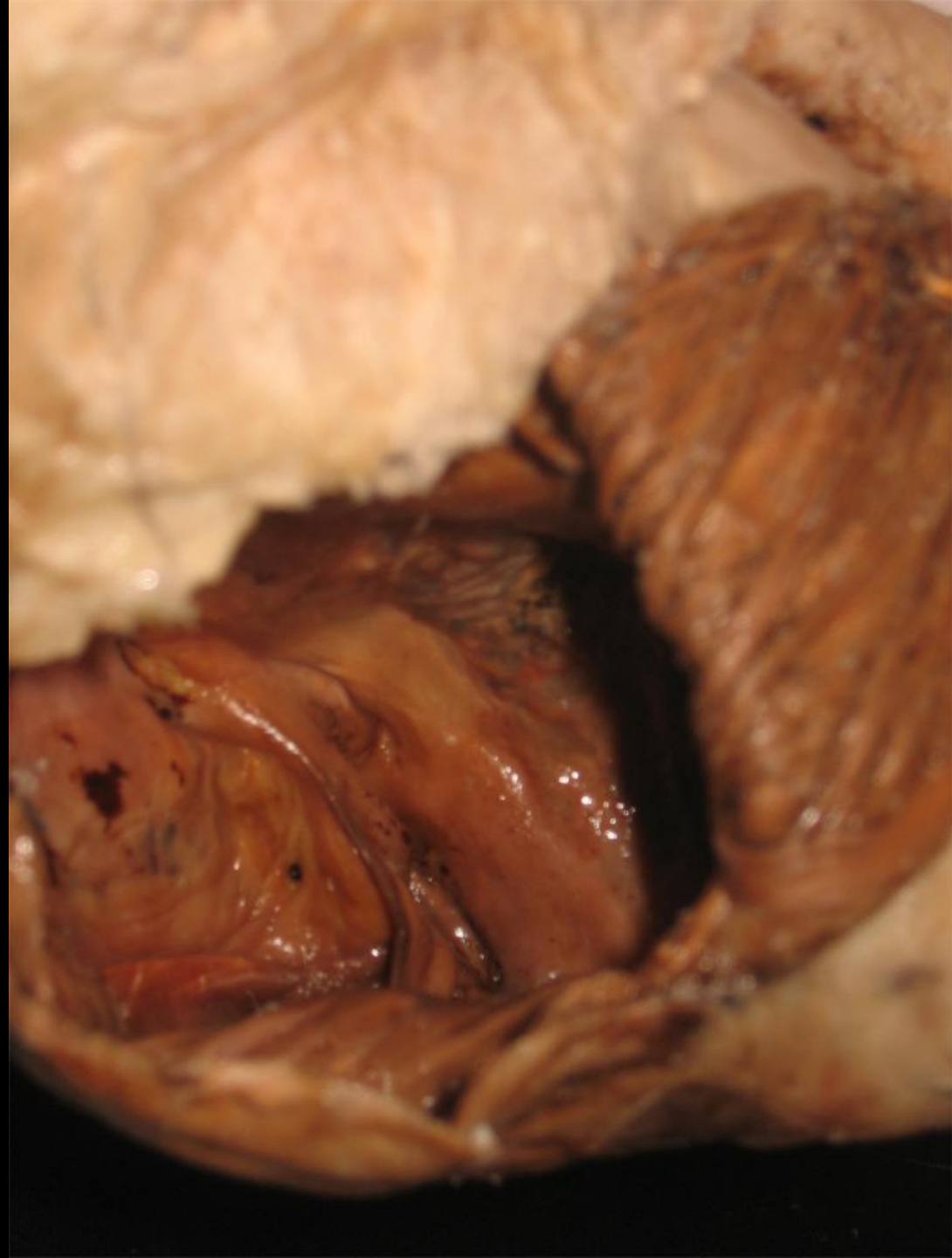FOSA
OVAL


Corazón plastinado



Corazón plastinado

DESEMBOCADURA
DEL SENO CORONARIO



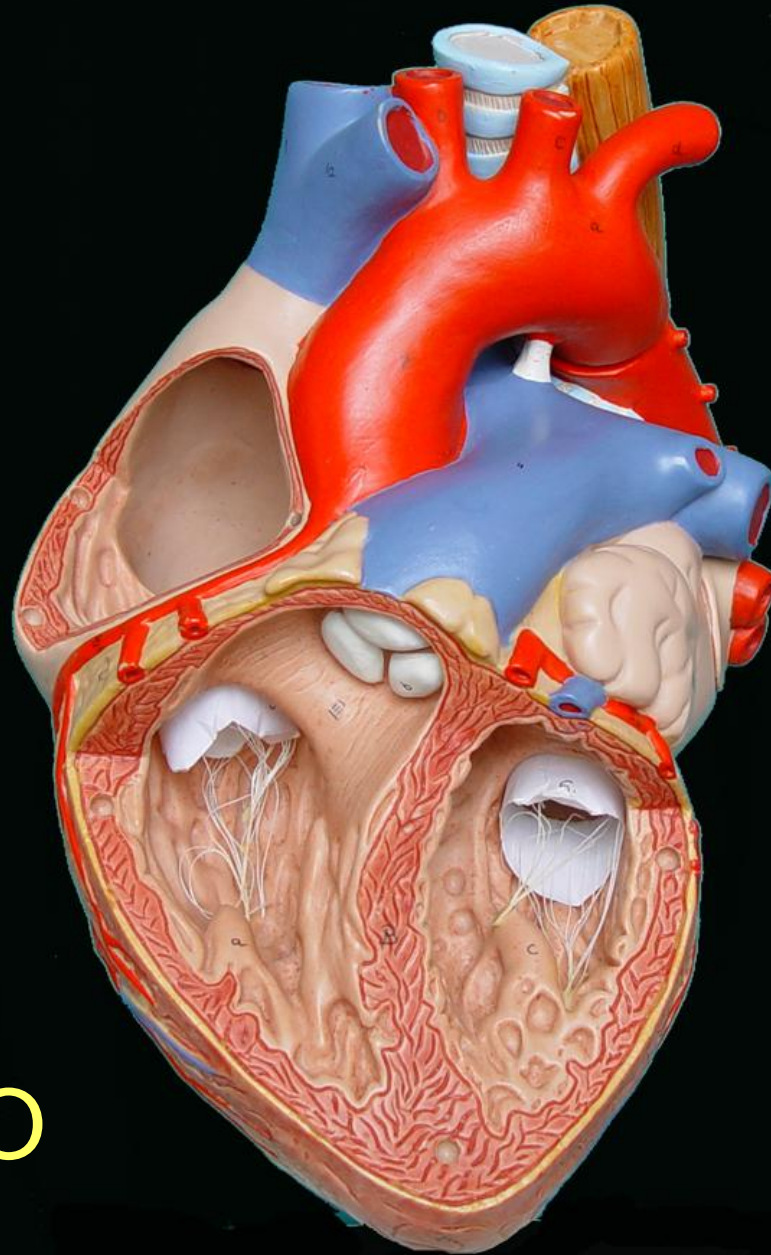
A detailed anatomical dissection of the left atrioventricular orifice and the tricuspid valve in a plastinated heart. The image shows the internal structure of the heart, including the atrial wall, the orifice, and the valve apparatus. The tricuspid valve is visible, showing its three leaflets and the chordae tendineae. The surrounding tissue is dark brown and appears to be preserved in a plastinated state. The text is overlaid in green on the image.

ORIFICIO AURICULO-
VENTRICULAR IZQUIERDO
VÁLVULA TRICÚSPIDE

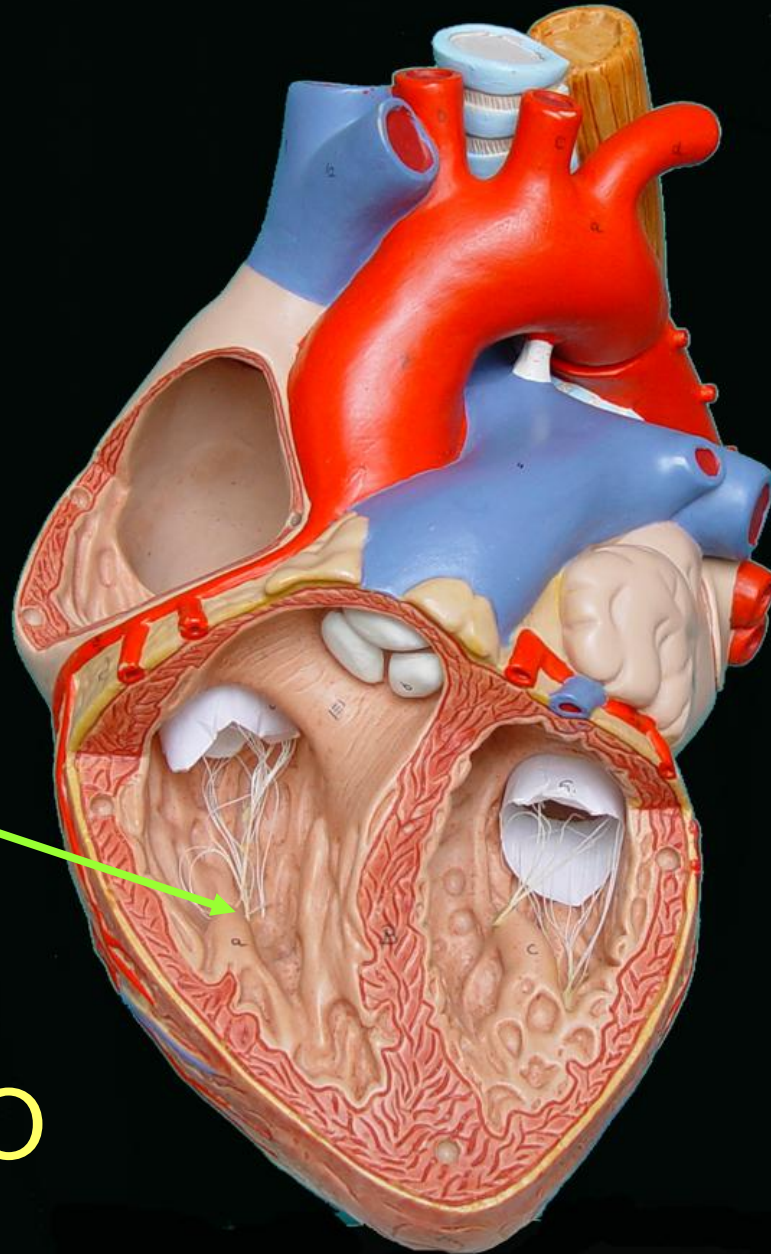
Corazón plastinado

ORIFICIO AURICULO-
VENTRICULAR IZQUIERDO
VÁLVULA TRICÚSPIDE

Corazón plastinado

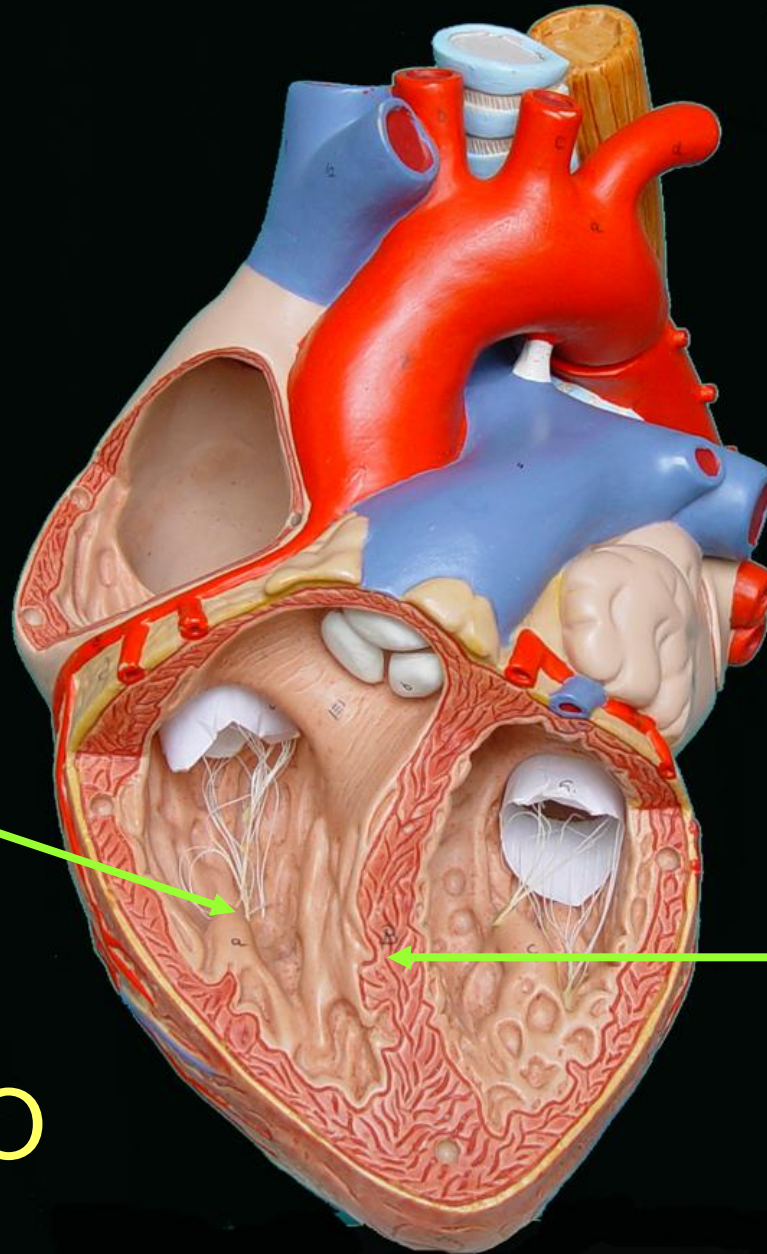


VENTRÍCULO
DERECHO



PARED INFERIOR

VENTRÍCULO
DERECHO



PARED INFERIOR

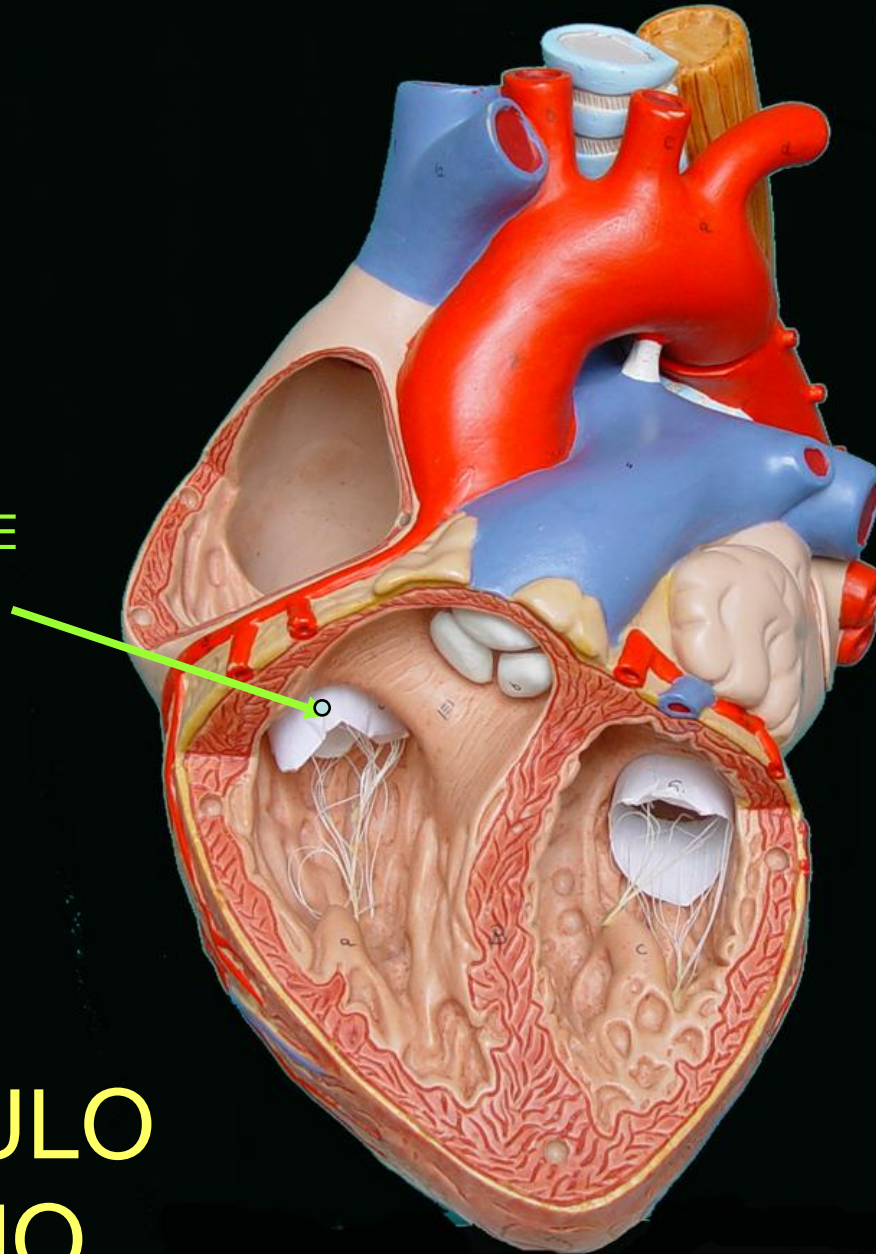
PARED INTERNA
O
TABIQUE
INTER-
VENTRICULAR

VENTRÍCULO
DERECHO

BASE

ORIFICIO
AURICULO-
VENTRICULAR
DERECHO
(VALVULA TRICUSPIDE
O
TRIGLOQUINA)

**VENTRÍCULO
DERECHO**

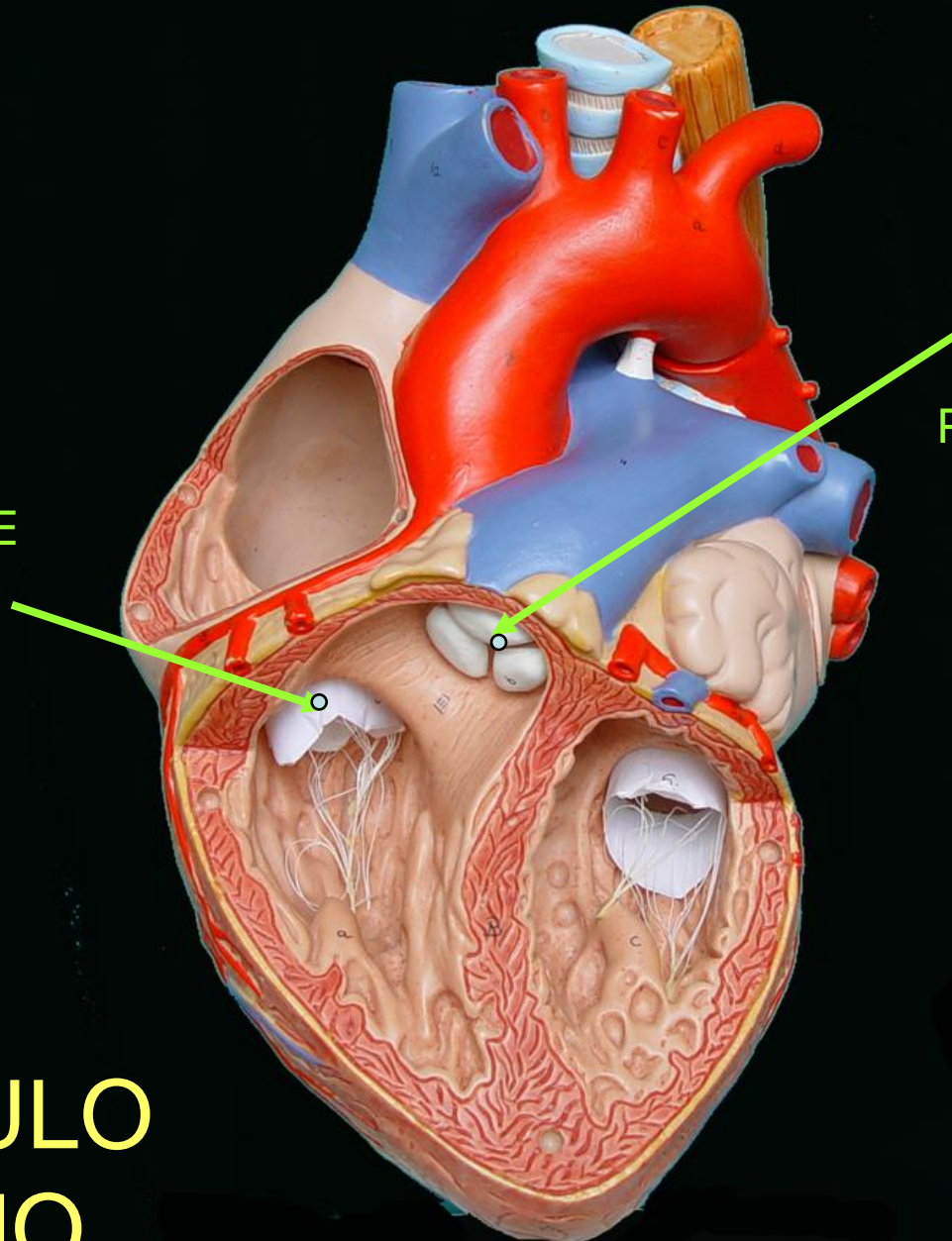


BASE

ORIFICIO
AURICULO-
VENTRICULAR
DERECHO
(VALVULA TRICUSPIDE
O
TRIGLOQUINA)

ORIFICIO
DE LA
ARTERIA
PULMONAR

**VENTRÍCULO
DERECHO**



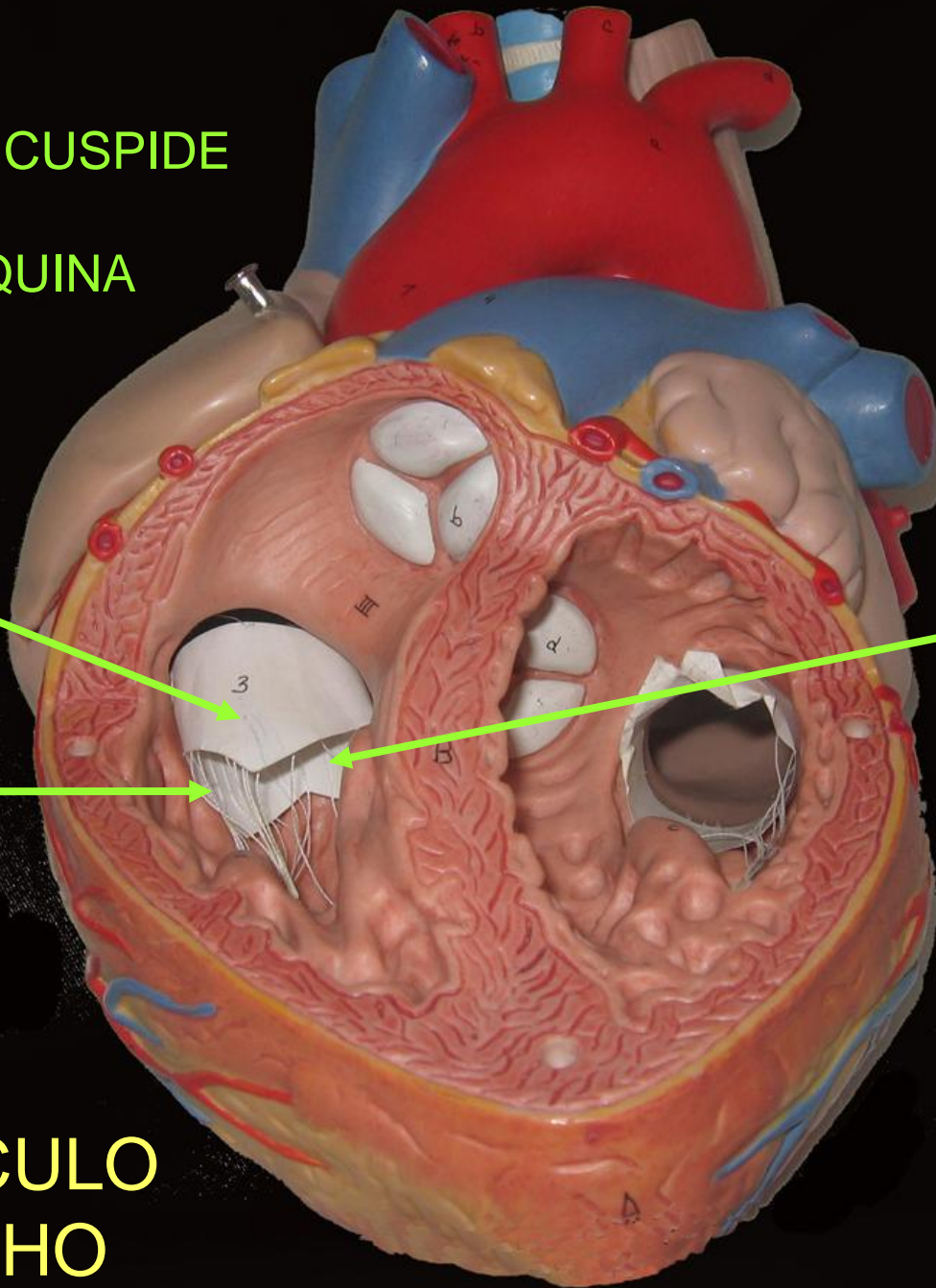
VALVULA TRICUSPIDE
O
TRIGLOQUINA

VALVA
ANTERIOR

VALVA
INTERNA

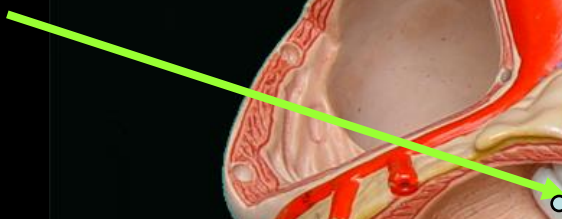
VALVA
INFERIOR

VENTRÍCULO
DERECHO

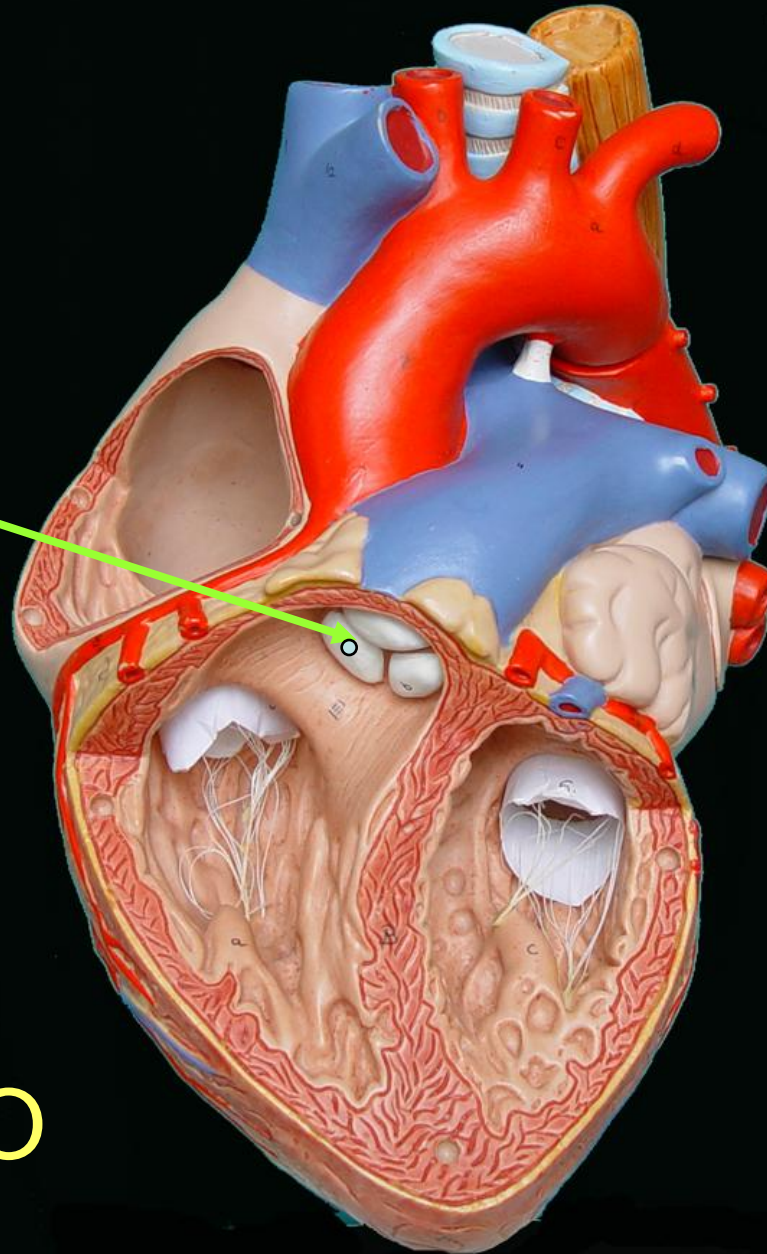


BASE

**ORIFICIO
DE LA
ARTERIA
PULMONAR**

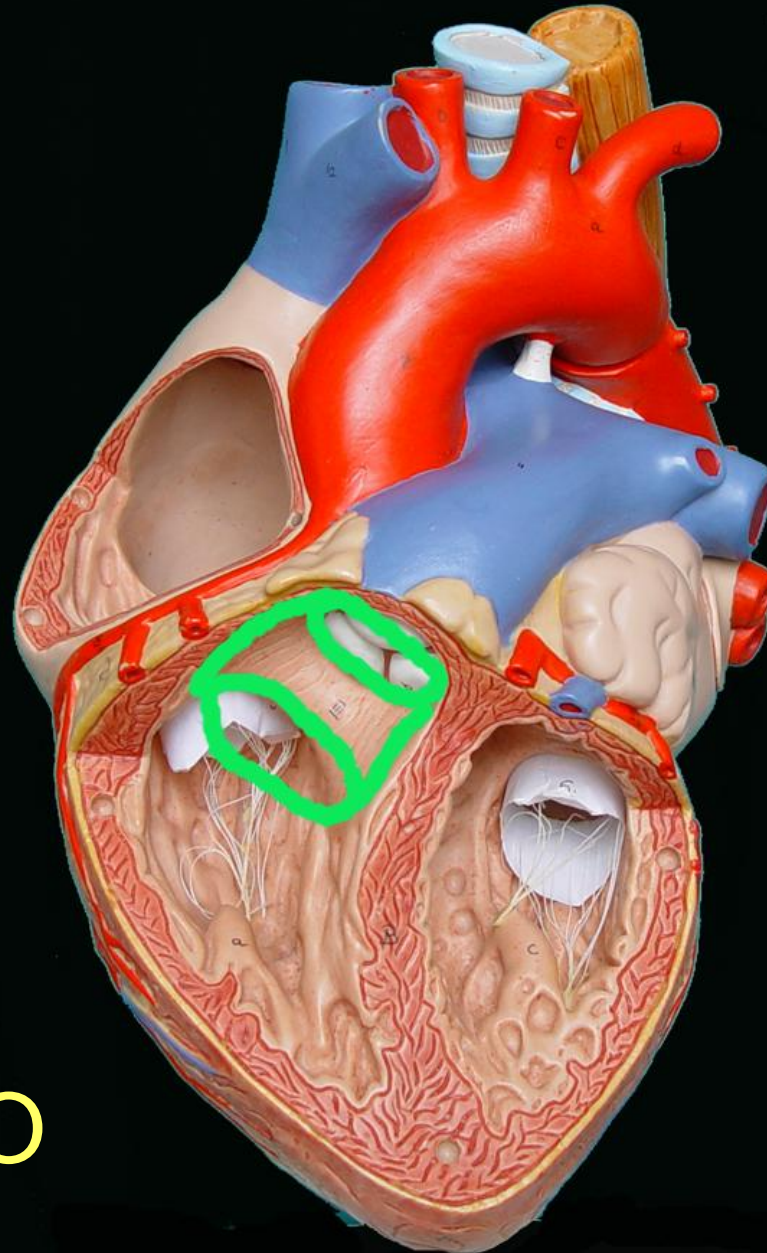


**VENTRÍCULO
DERECHO**



BASE

ORIFICIO
DE LA
ARTERIA
PULMONAR,
CONO ARTERIAL
O INFUNDÍBULO



VENTRÍCULO DERECHO

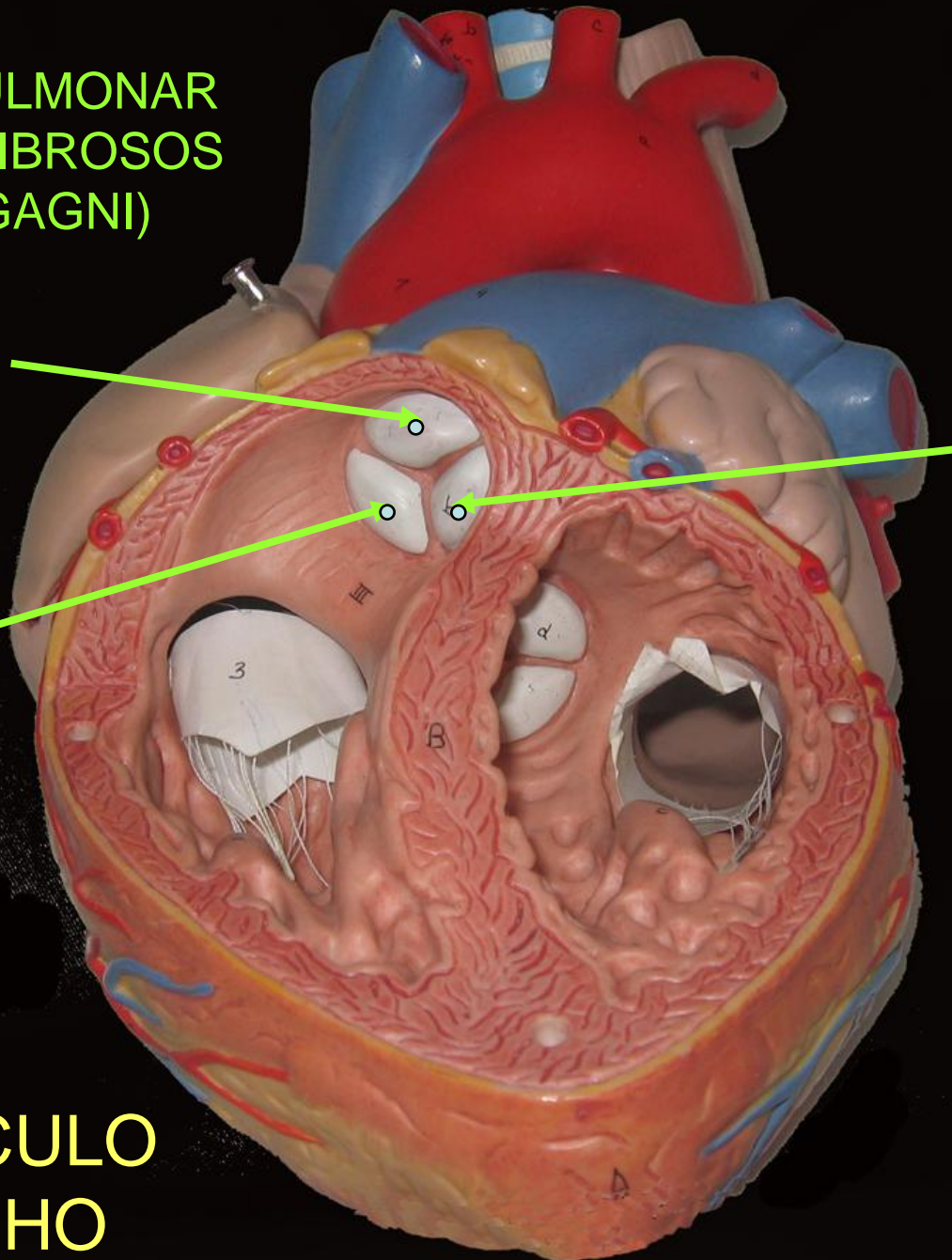
VALVULA PULMONAR
(NODULOS FIBROSOS
DE MORGAGNI)

VALVULA
SIGMOIDEA
ANTERIOR

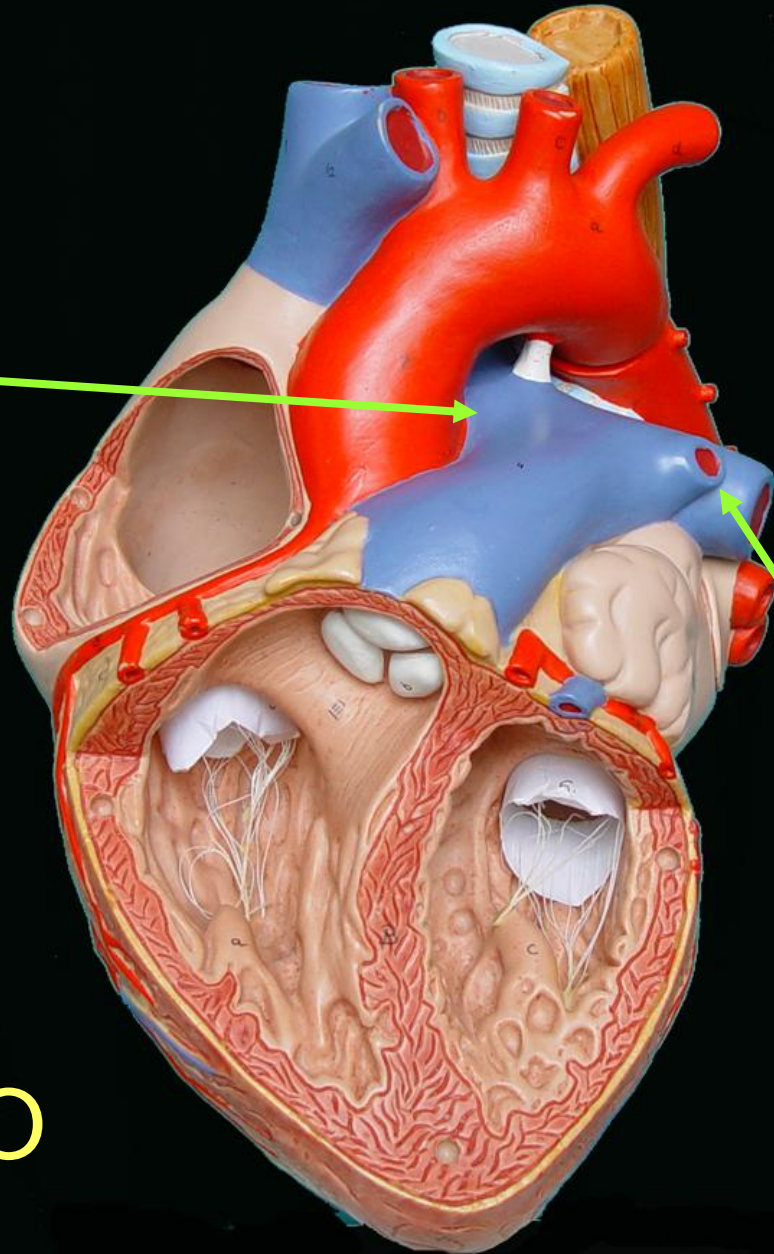
VALVULA
SIGMOIDEA
POSTERO-
IZQUIERDA

VALVULA
SIGMOIDEA
POSTERO-
DERECHA

VENTRÍCULO
DERECHO

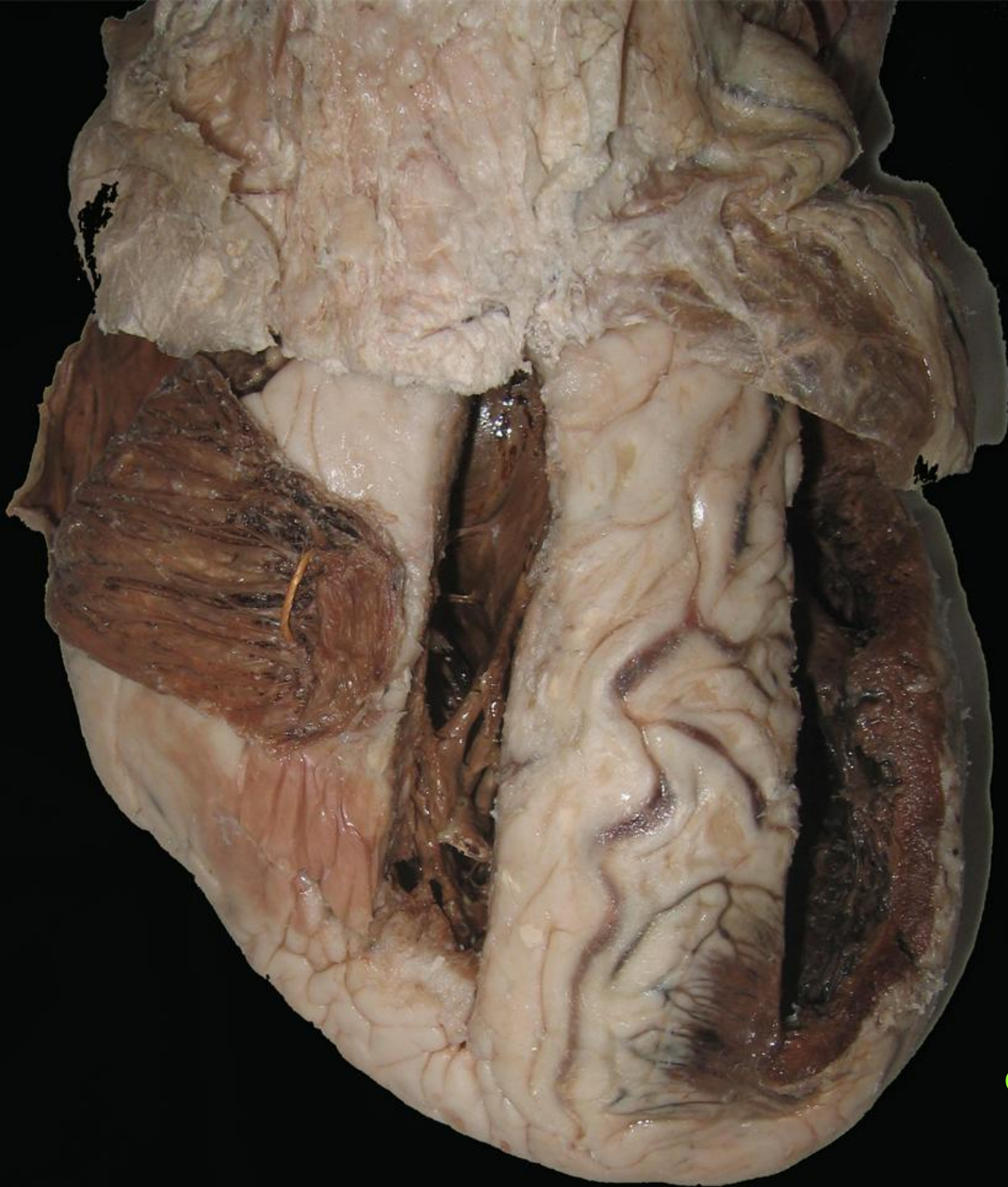


ARTERIA
PULMONAR
DERECHA

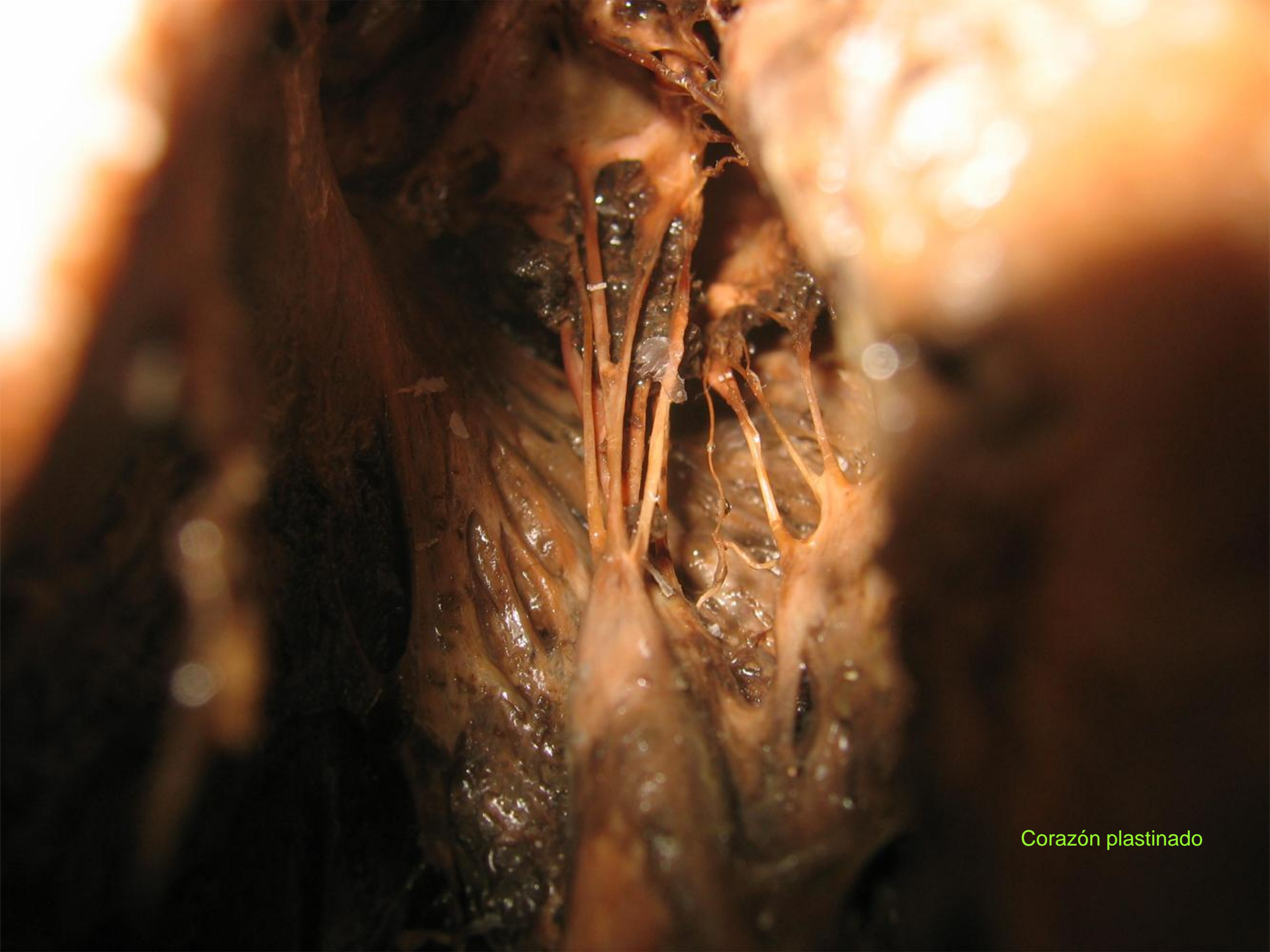

ARTERIA
PULMONAR
IZQUIERDA

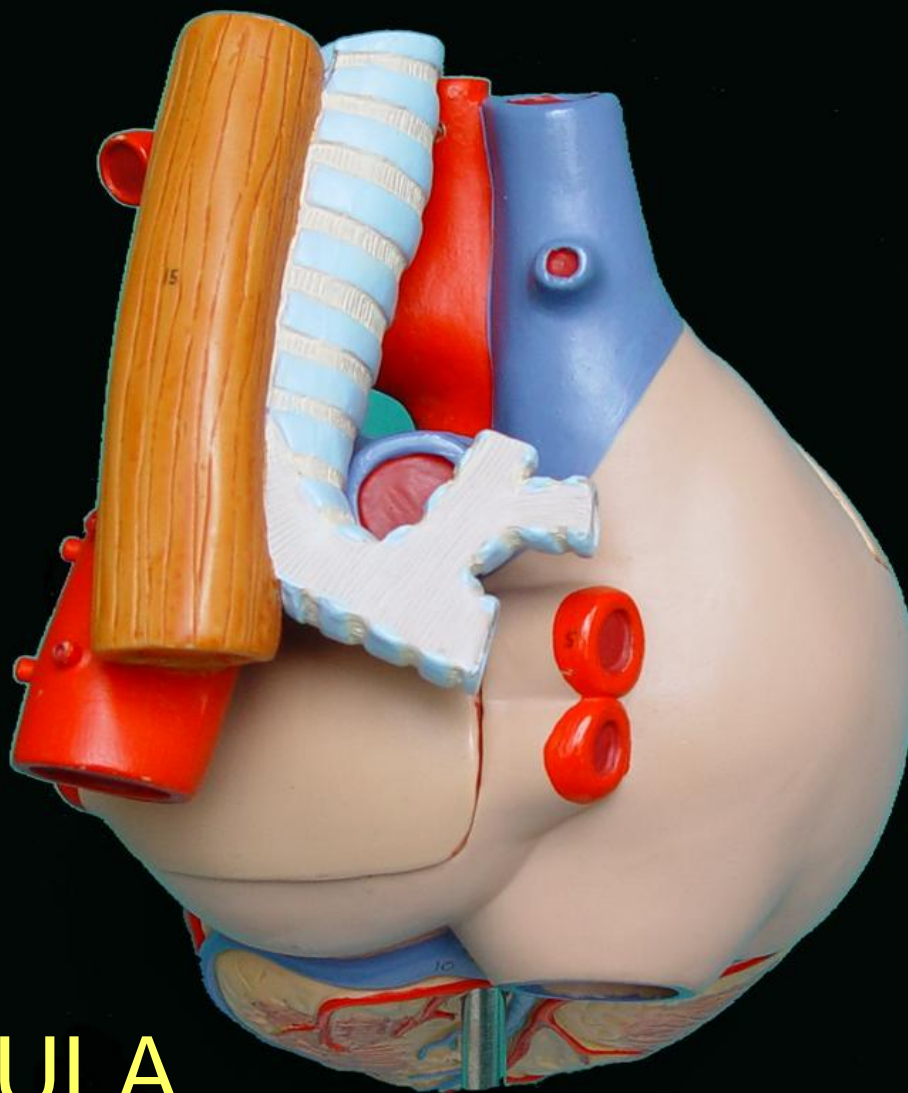
VENTRÍCULO
DERECHO



Corazón plastinado



Corazón plastinado



AURICULA
IZQUIERDA

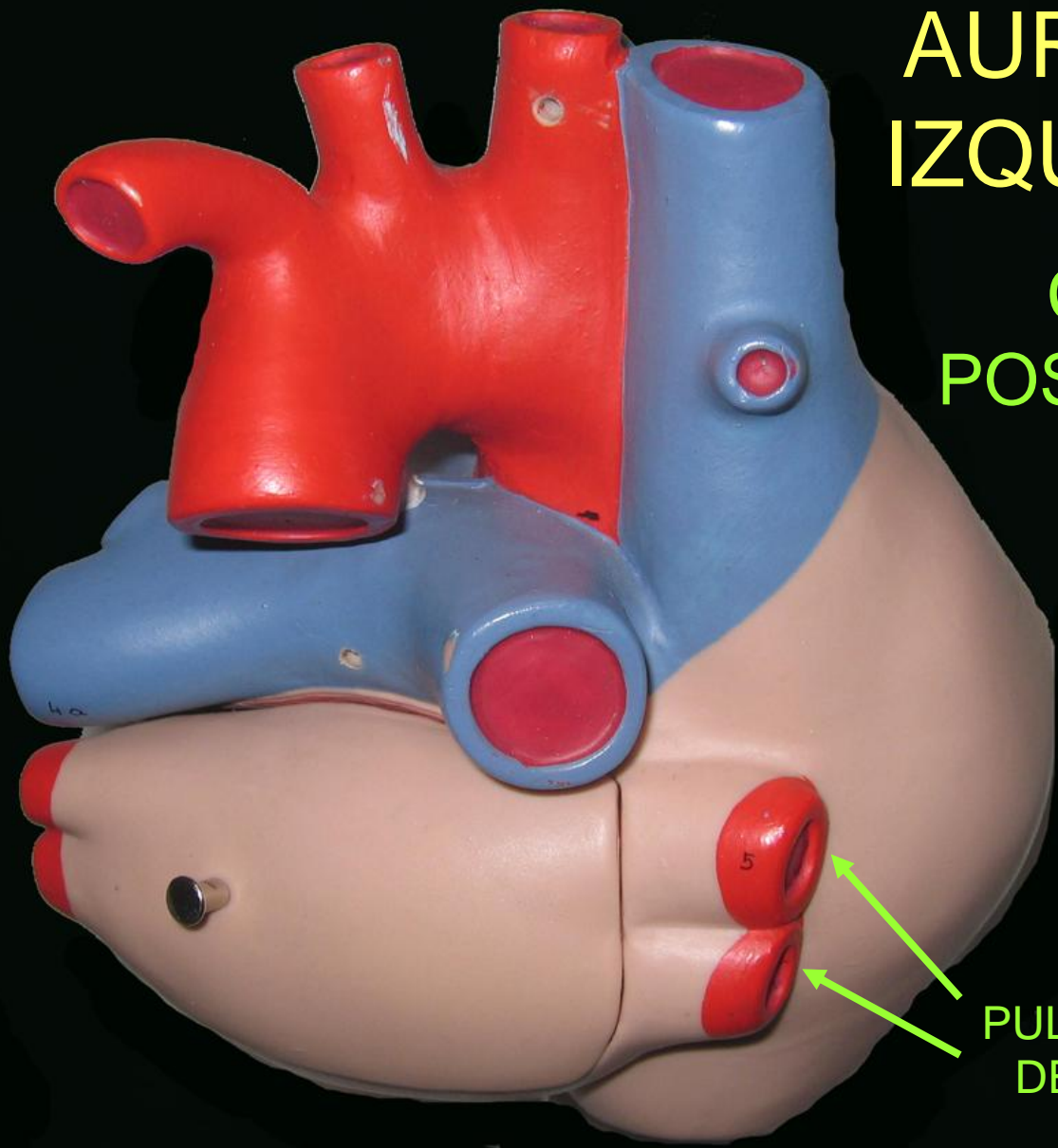
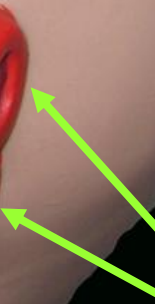AURICULA
IZQUIERDA

CARA
POSTERIOR

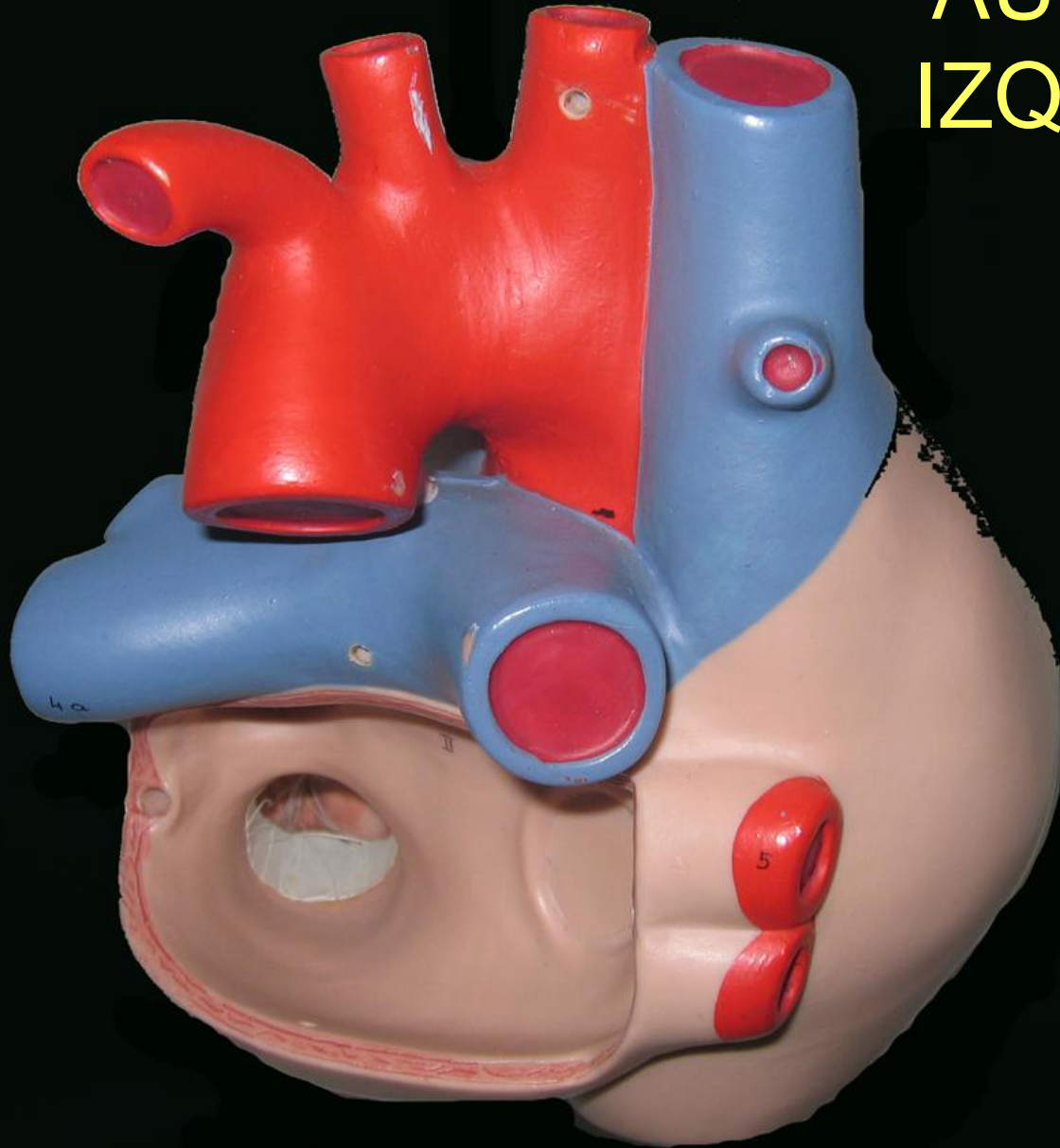
VENAS
PULMONARES
IZQUIERDAS



VENAS
PULMONARES
DERECHAS



AURICULA IZQUIERDA

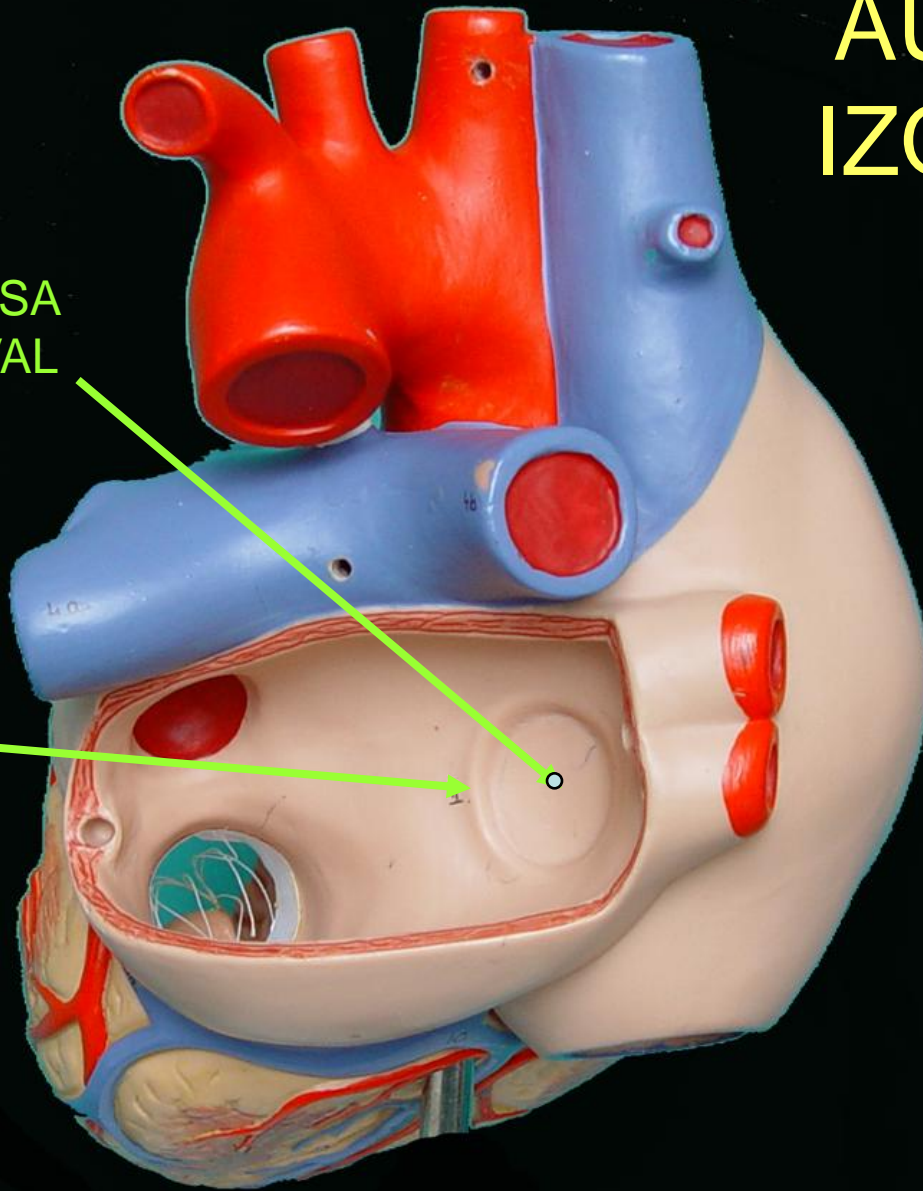


AURICULA IZQUIERDA

CARA
INTERNA

FOSA
OVAL

REPLIEGUE
SEMILUNAR

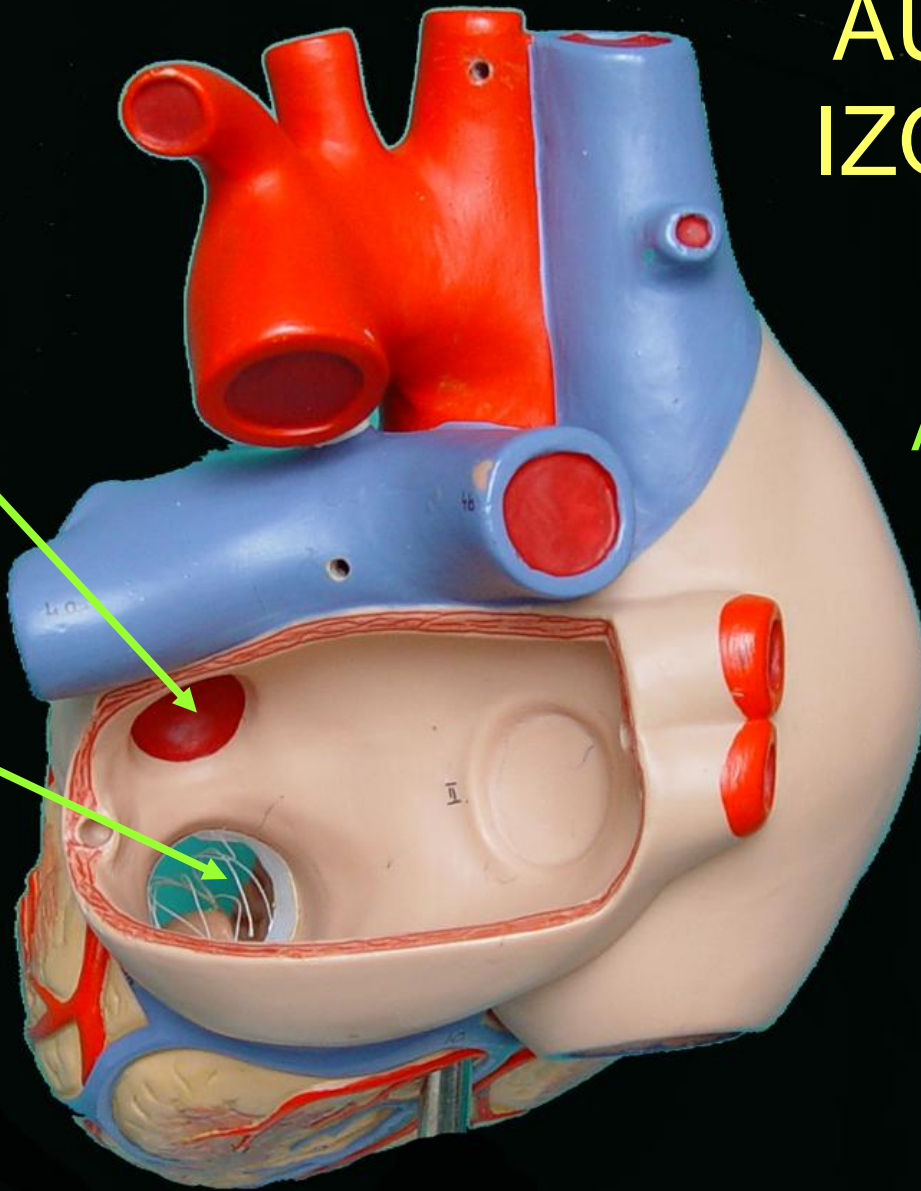


AURICULA IZQUIERDA

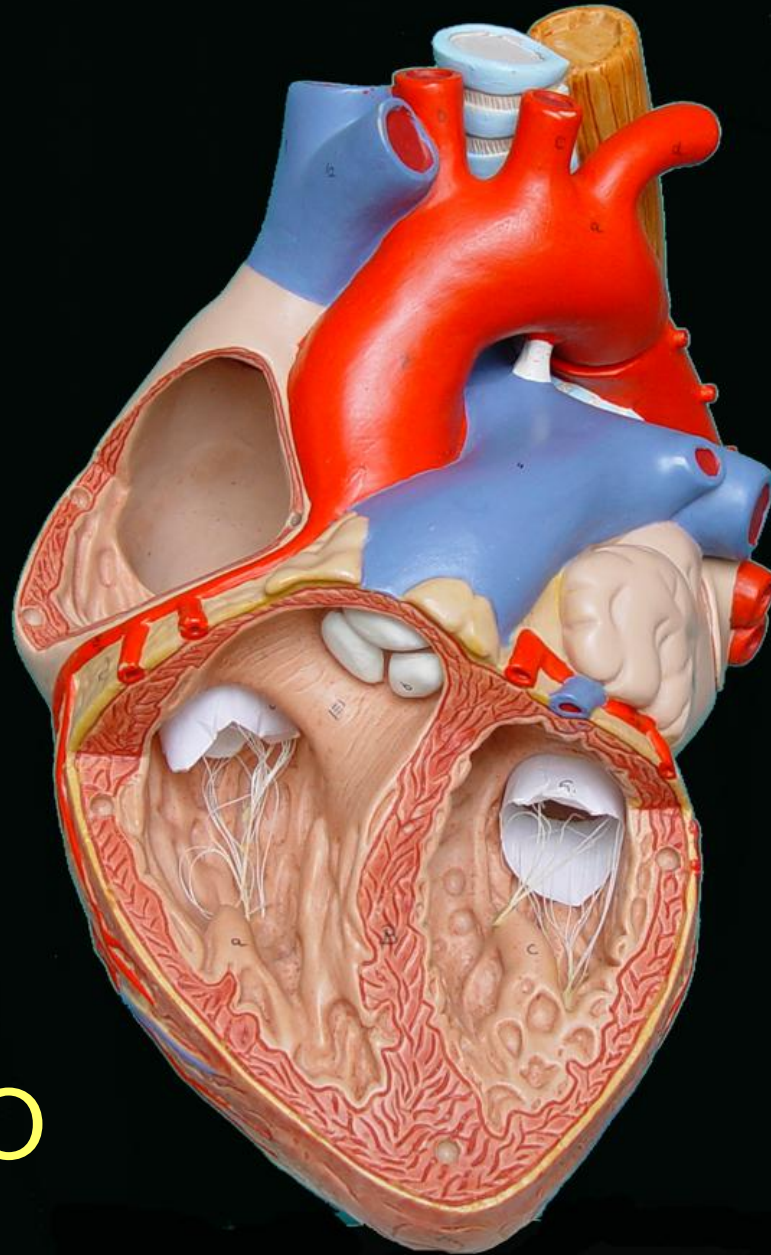
CARA
ANTERIOR

ORIFICIO
DE
ENTRADA
OREJUELA
IZQUIERDA

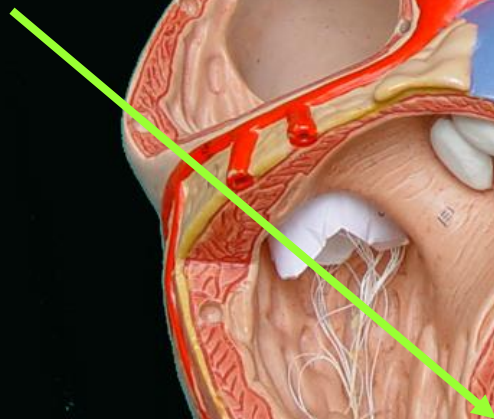
ORIFICIO
AURICULO-
VENTRICULAR
IZQUIERDO



VENTRÍCULO IZQUIERDO



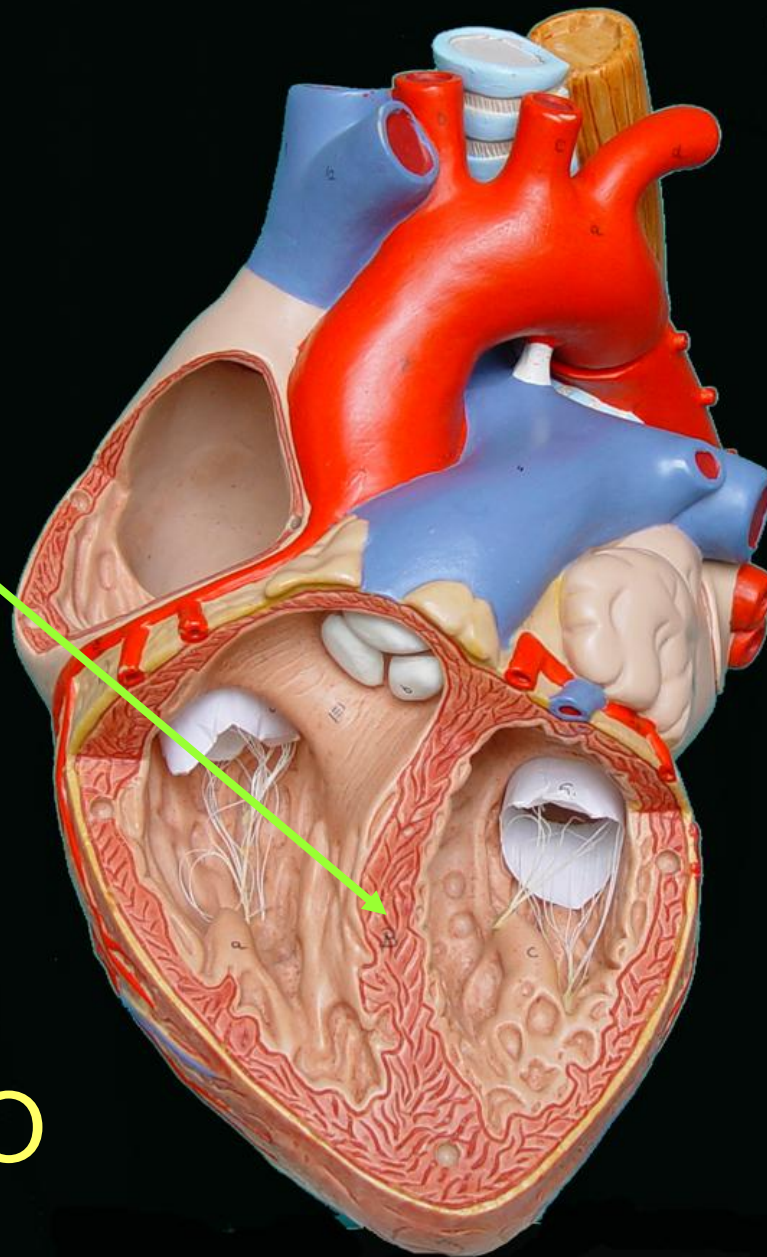
TABIQUE
INTERVENTRICULAR



BASE

VENTRÍCULO
IZQUIERDO

VÉRTICE

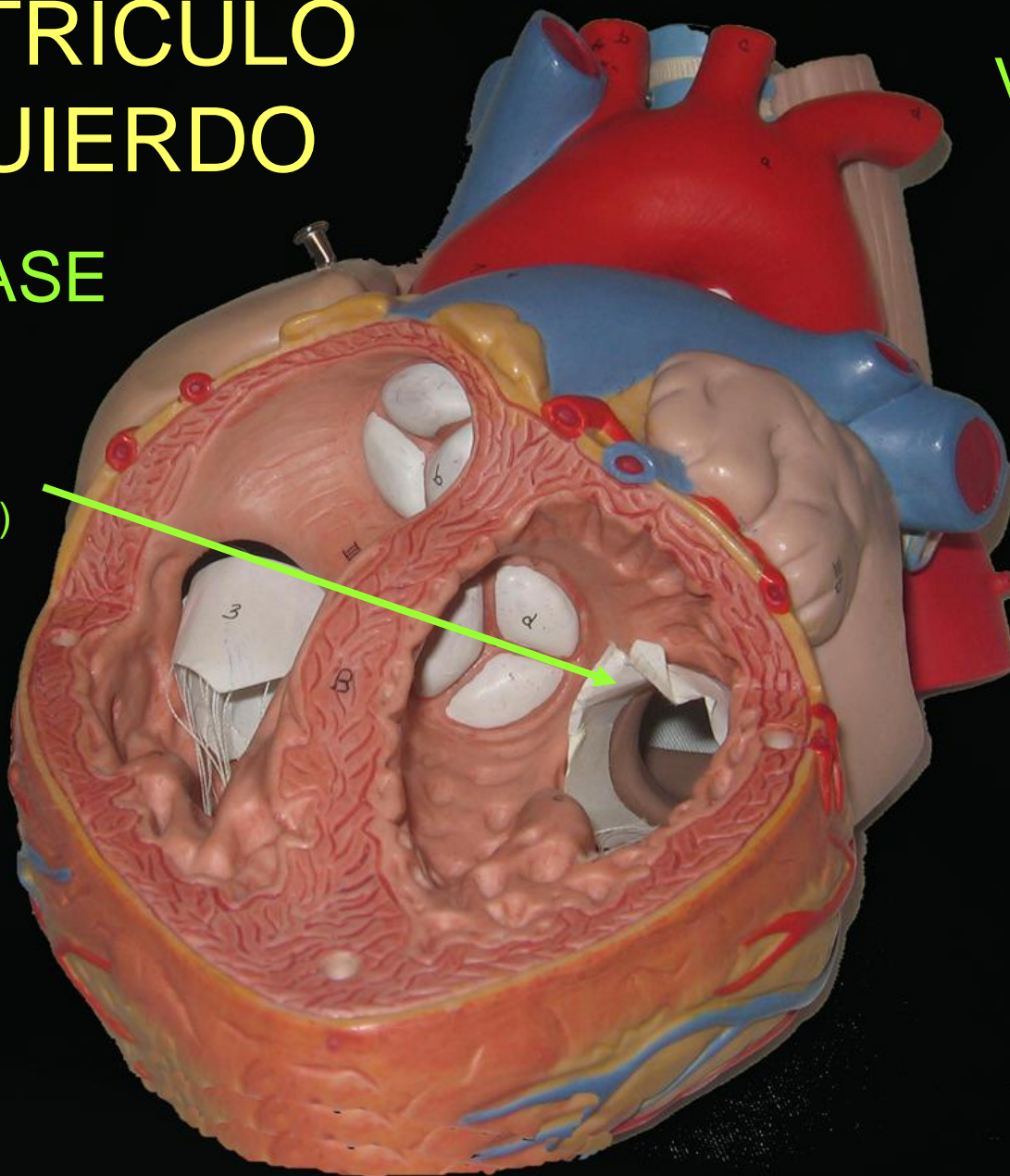


VENTRÍCULO IZQUIERDO

VÁLVULA
MITRAL

BASE

VALVA
DERECHA
(ANTERIOR)

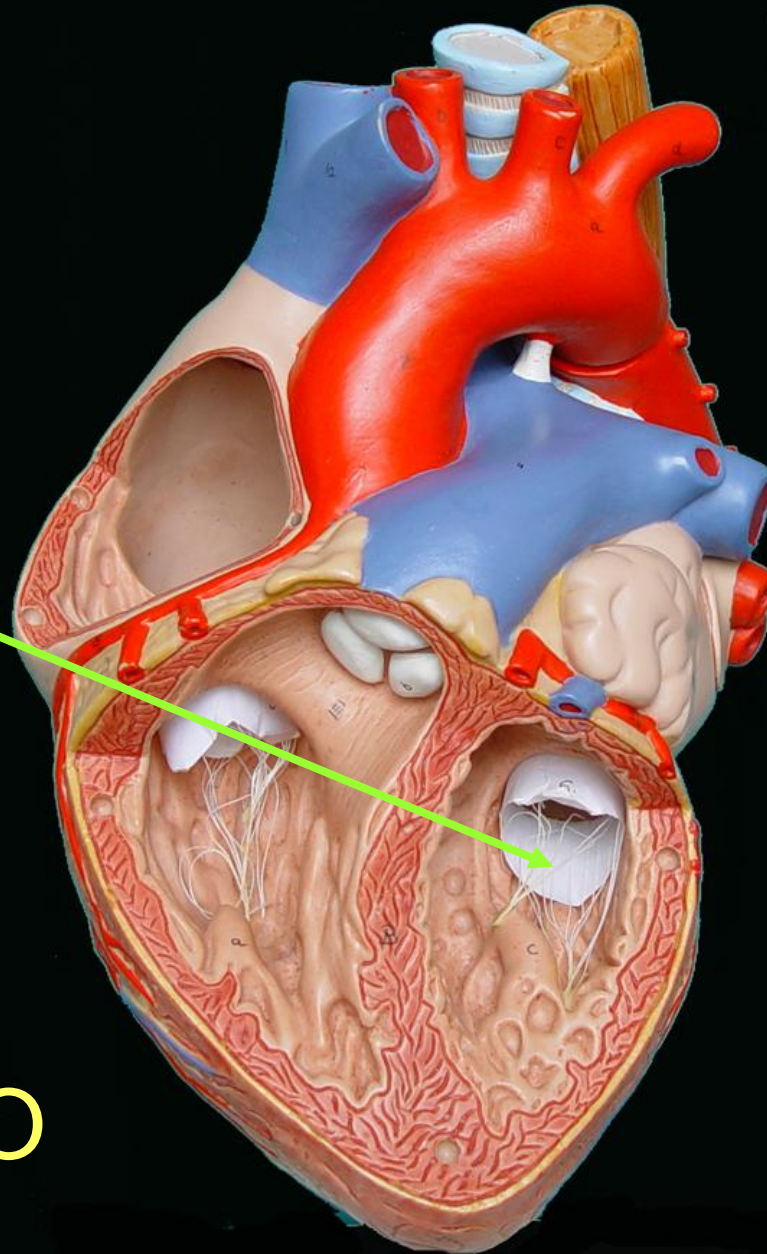


VÁLVULA
MITRAL

VALVA
IZQUIERDA
(POSTERIOR)

BASE

VENTRÍCULO
IZQUIERDO



VENTRÍCULO IZQUIERDO

BASE

VALVULA
AORTICA
(NODULOS FIBROSOS
DE ARANCIO)

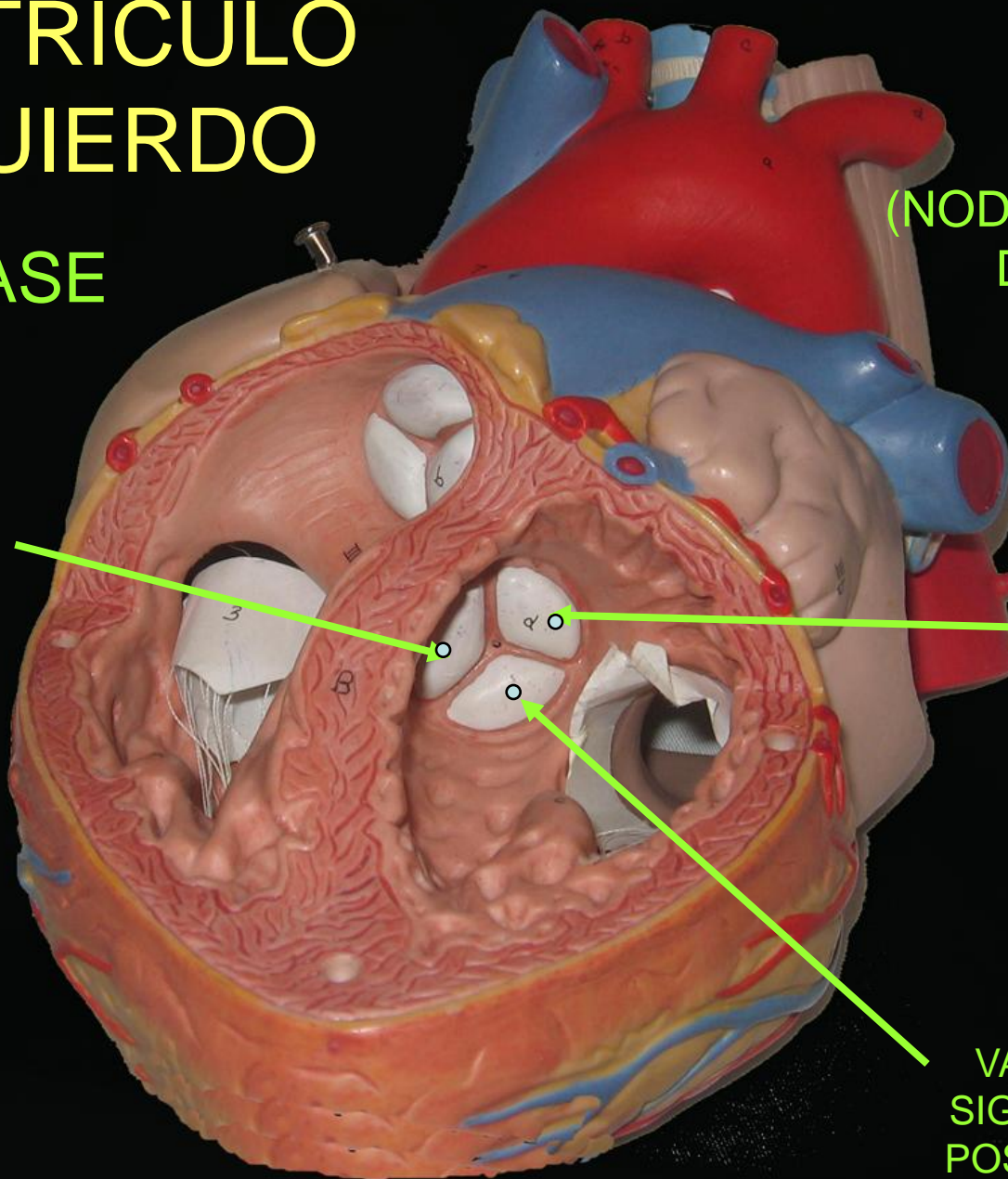
VALVULA
SIGMOIDEA
ANTERIOR
DERECHA

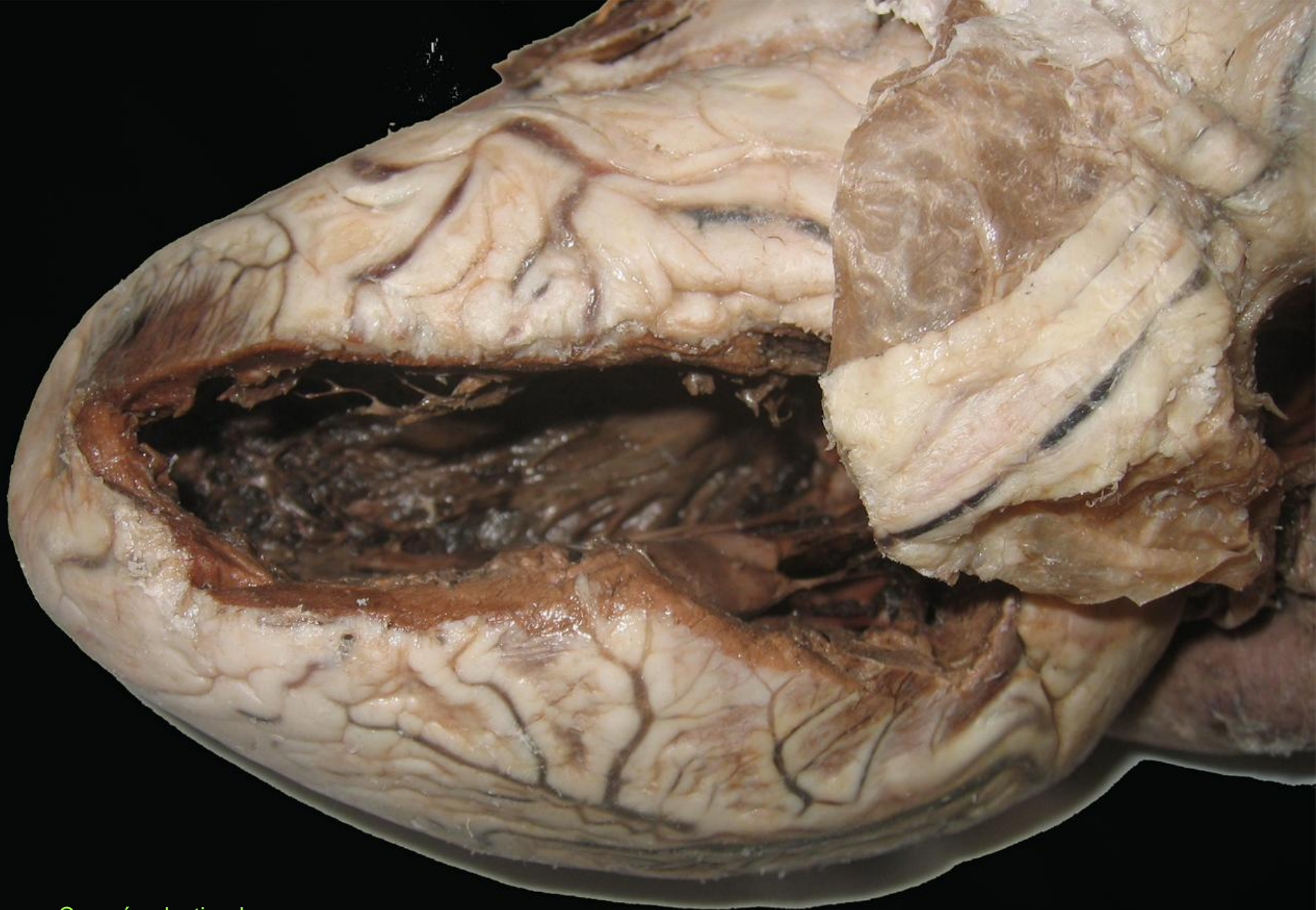(ARTERIA
CORONARIA
DERECHA)

VALVULA
SIGMOIDEA
ANTERIOR
IZQUIERDA

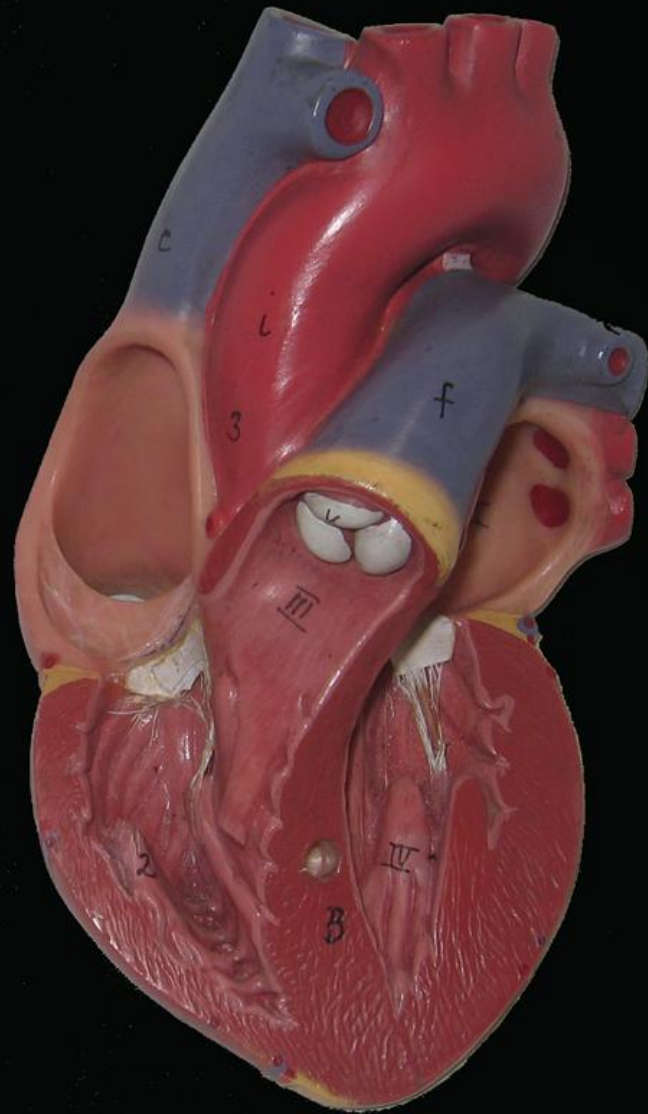
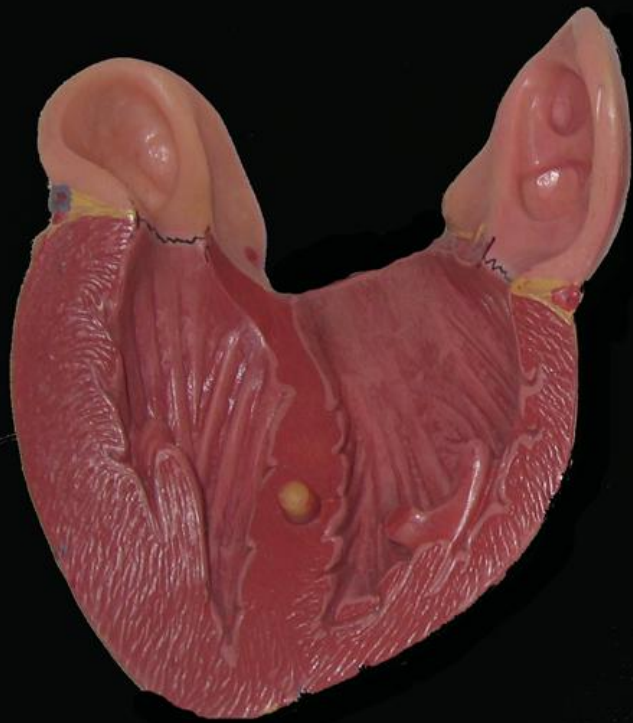
(ARTERIA
CORONARIA
IZQUIERDA)

VALVULA
SIGMOIDEA
POSTERIOR

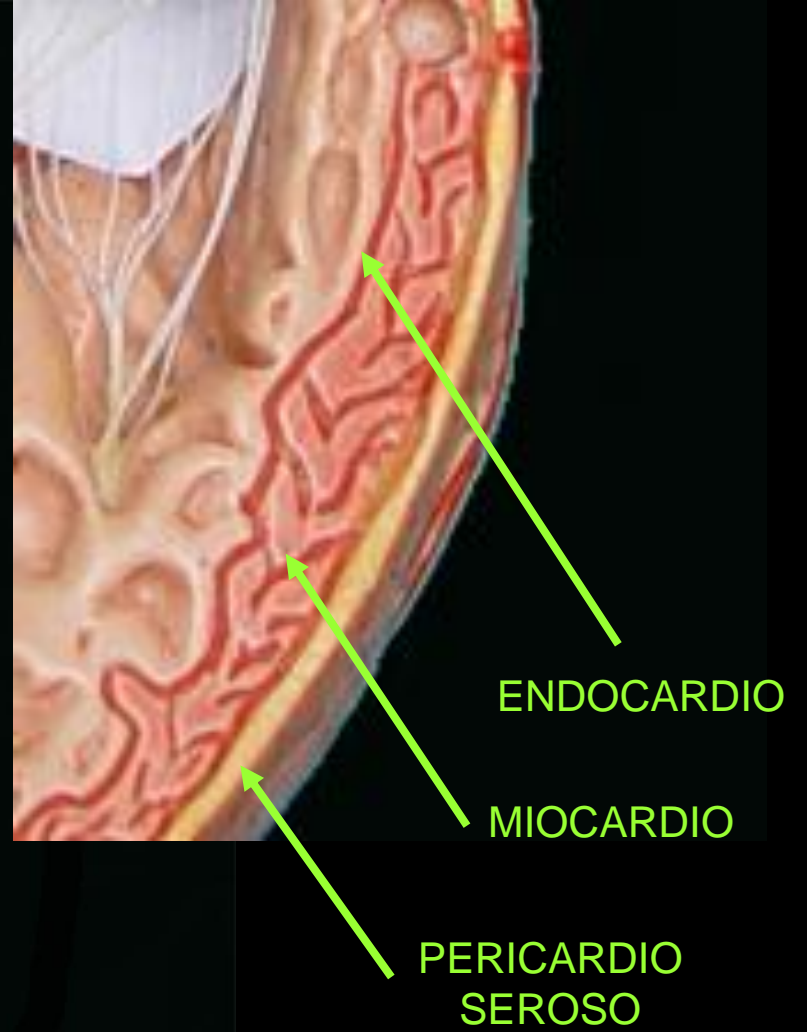
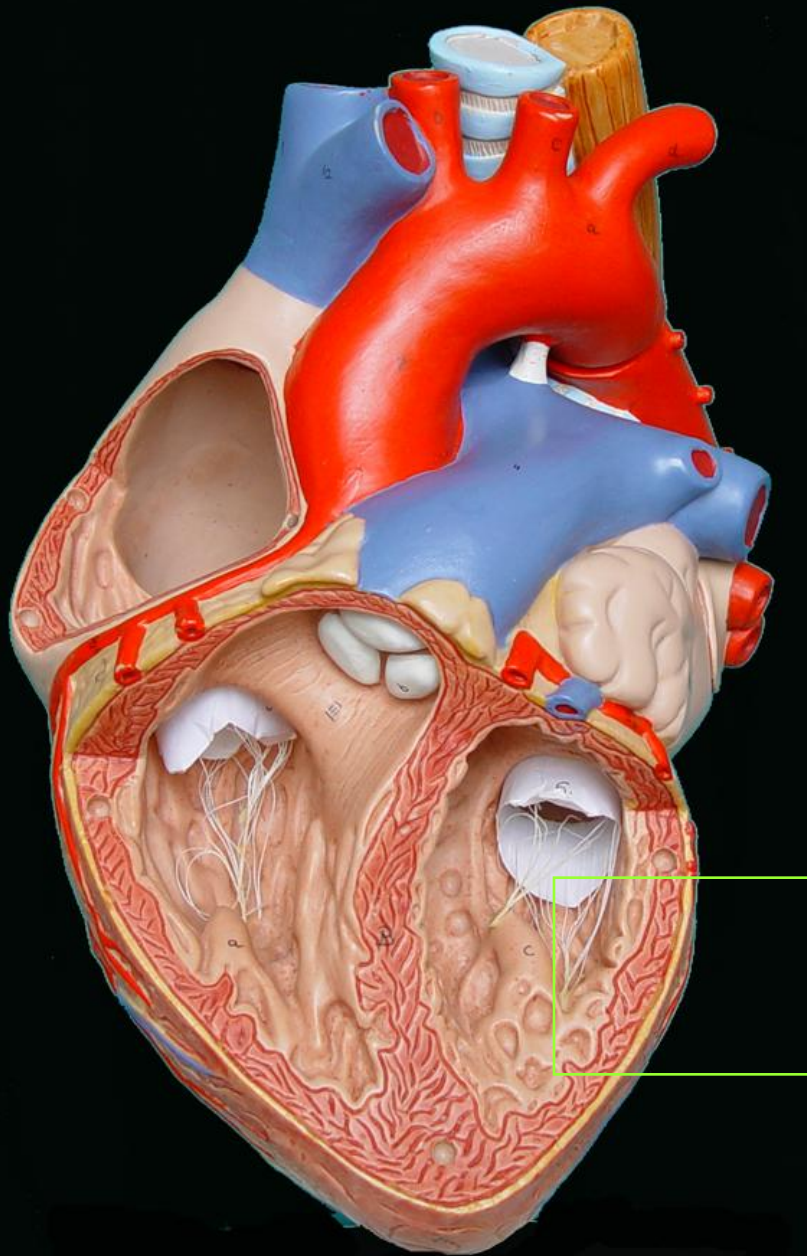


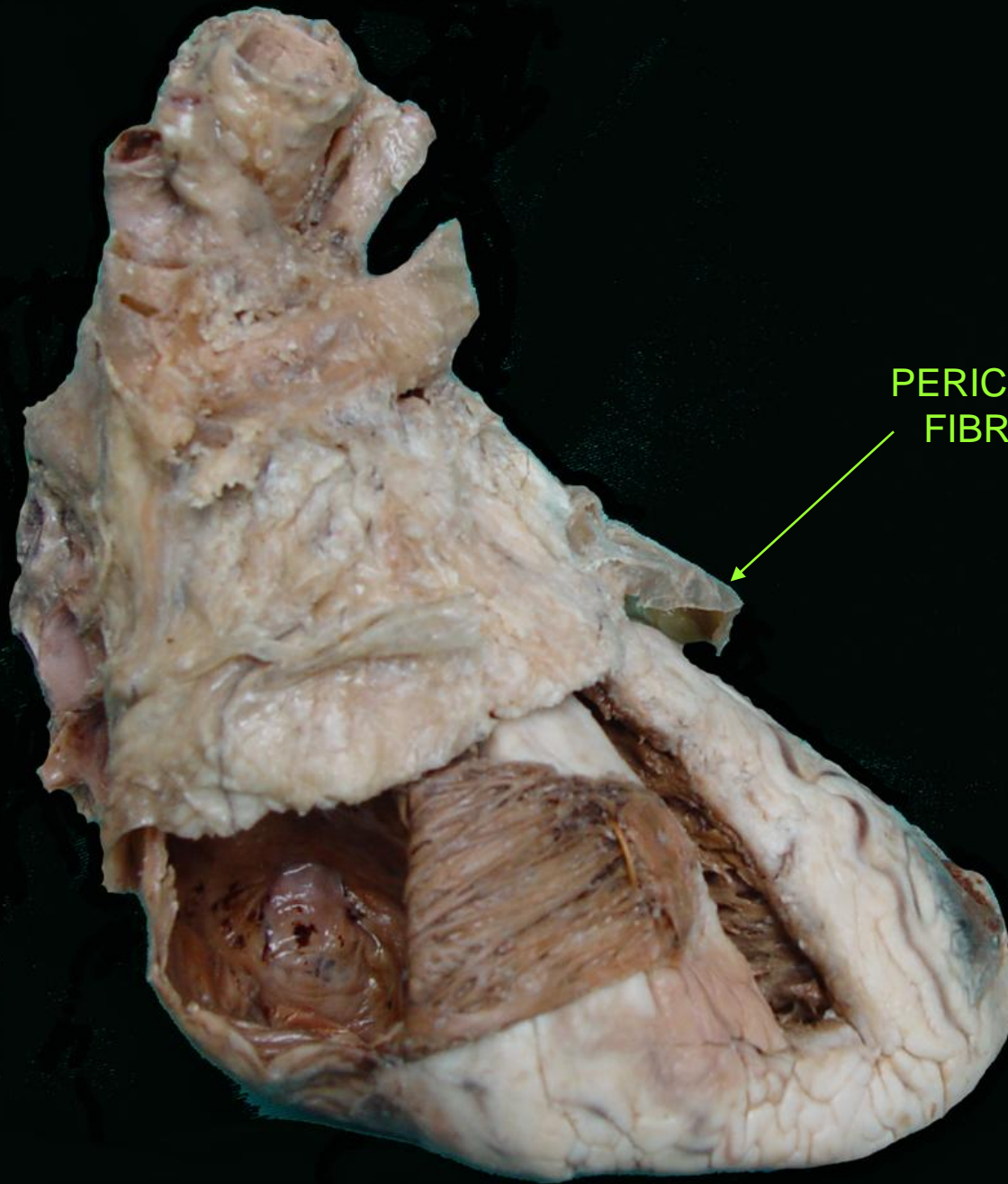


Corazón plastinado



ESTRUCTURA CARDIACA





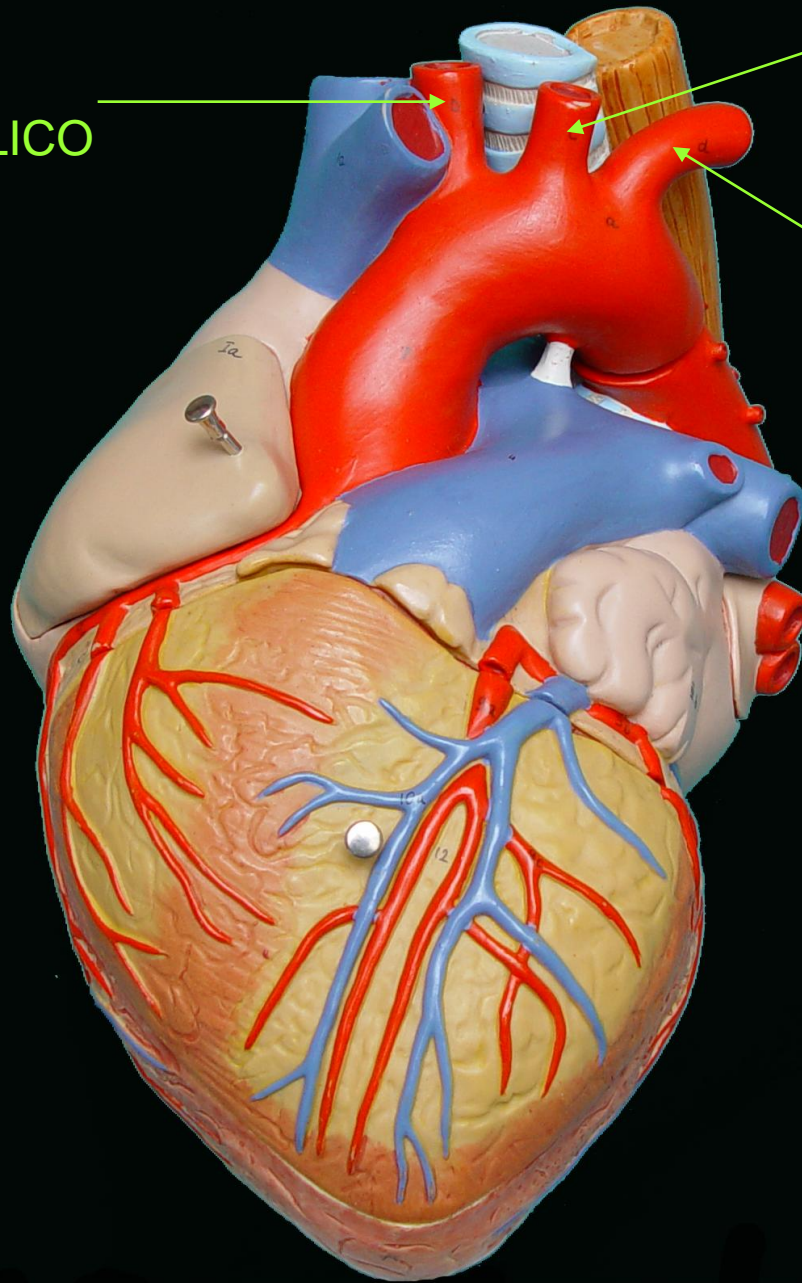
PERICARDIO
FIBROSO

Corazón plastinado

**AÓRTA,
TRÁQUEA Y
ESÓFAGO**

TRONCO
BRAQUIO-CEFÁLICO

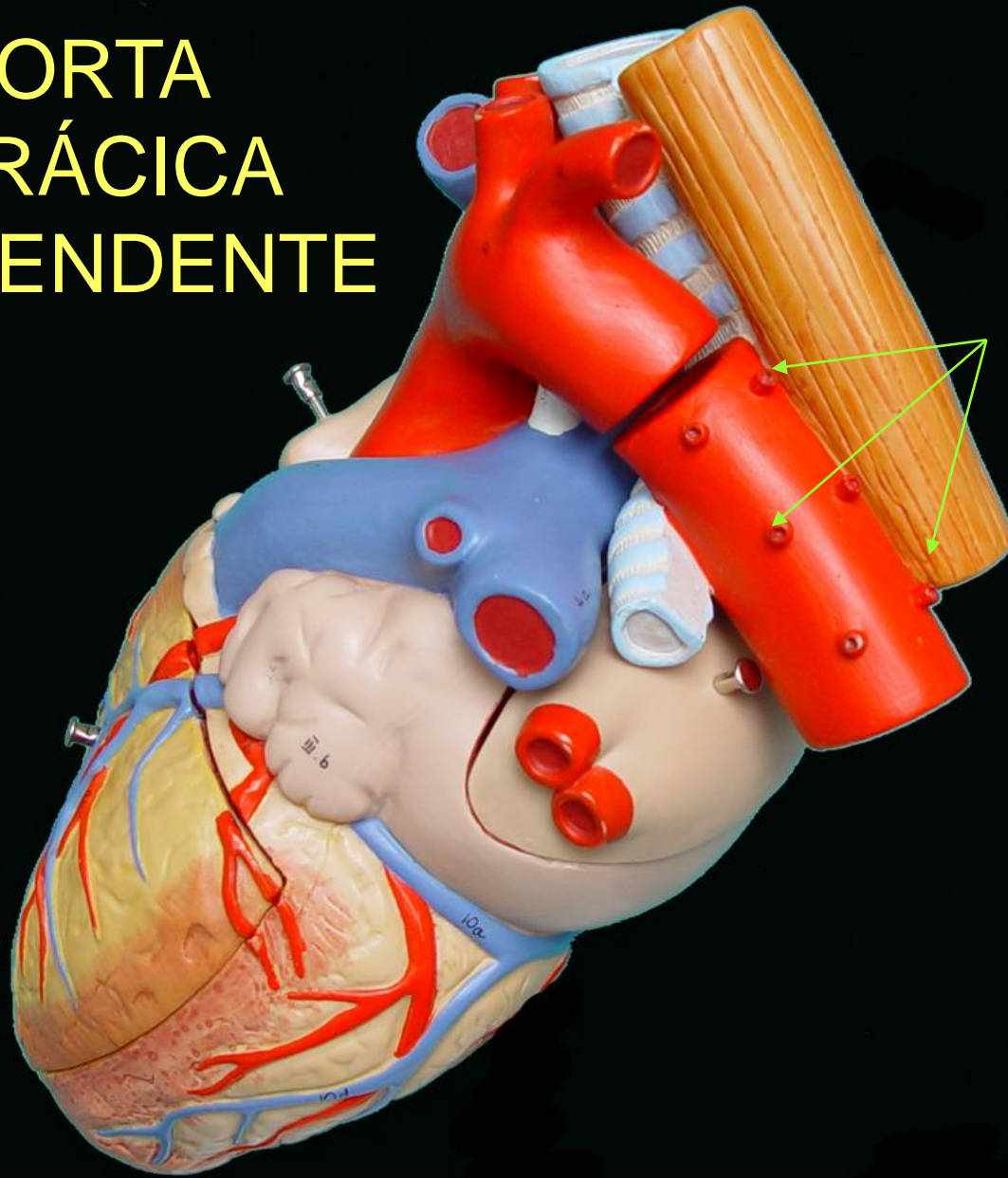
CAYADO
DE LA
AORTA



ARTERIA CAROTIDA
COMUN O PRIMITIVA
IZQUIERDA


ARTERIA SUBCLAVIA
IZQUIERDA

AORTA TORÁCICA DESCENDENTE

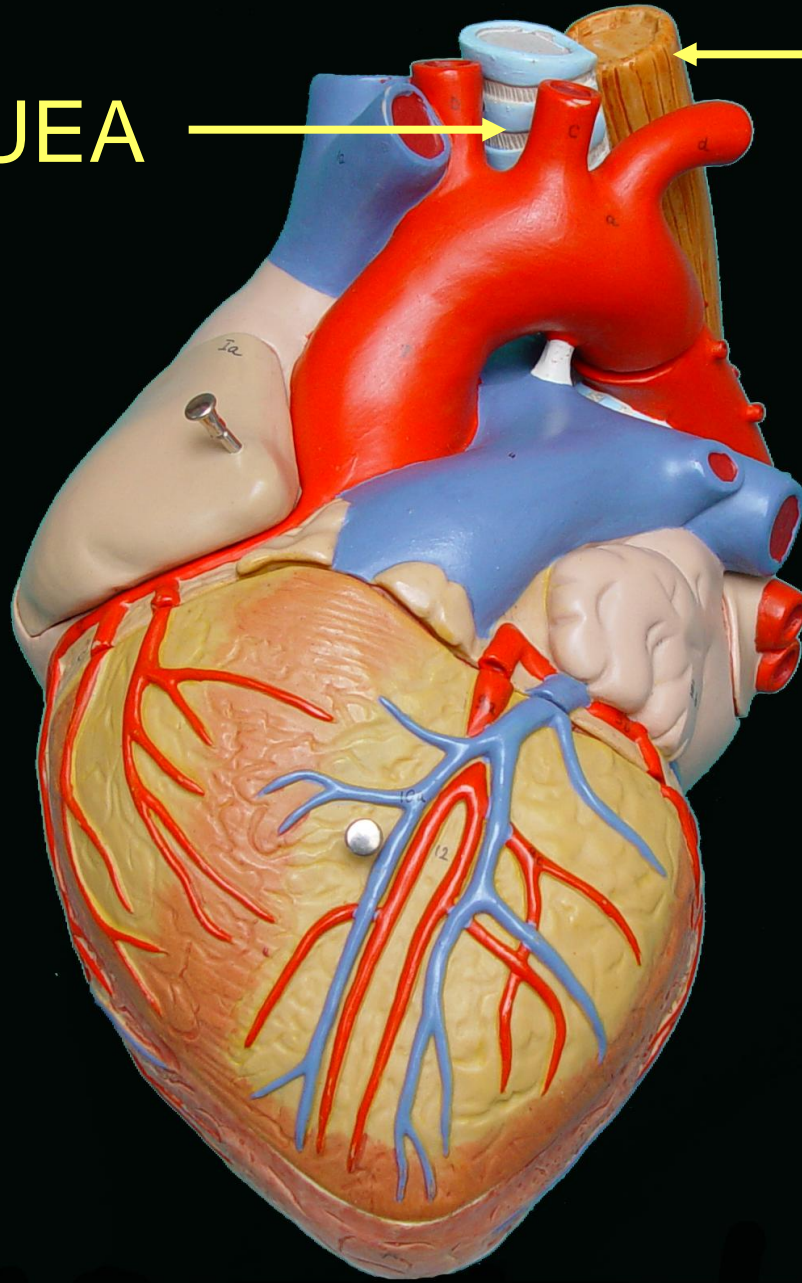



ARTERIAS
INTERCOSTALES

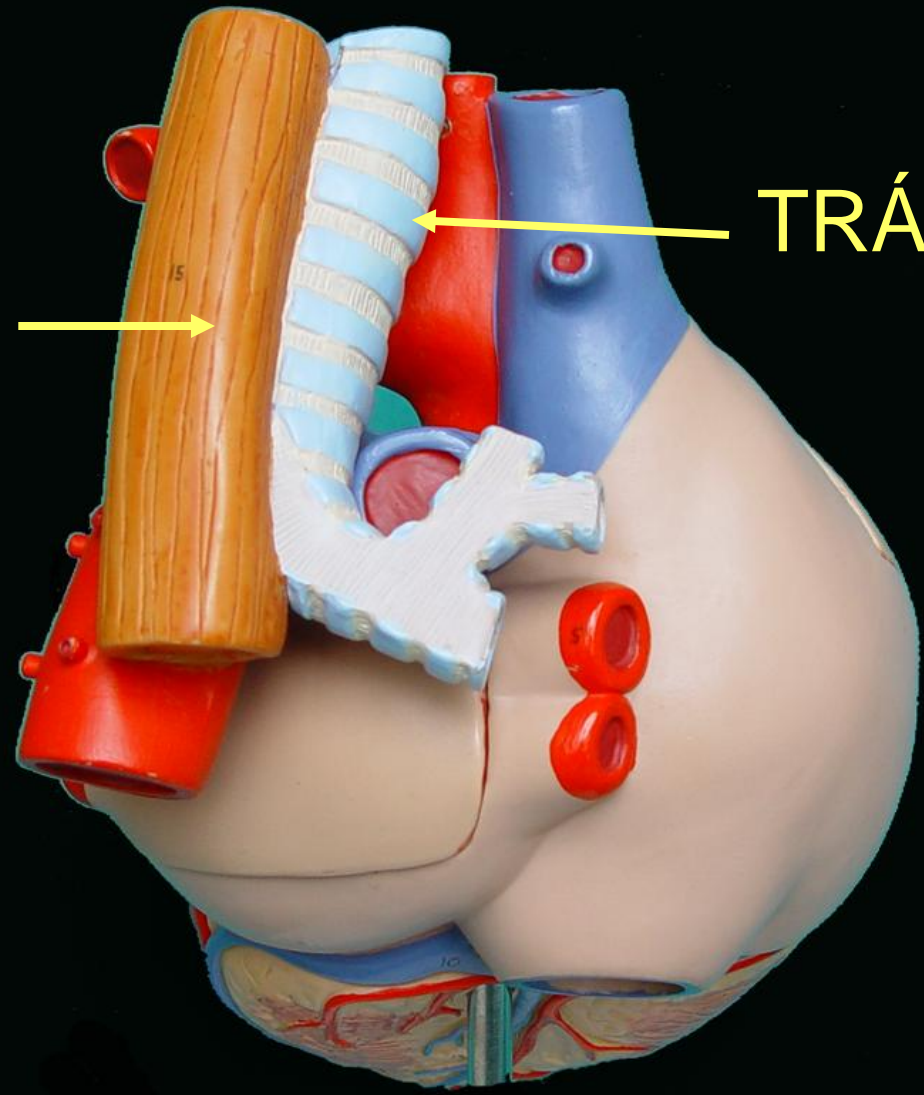
TRÁQUEA



ESÓFAGO



ESÓFAGO



TRÁQUEA



FIN