

Original Article

Role of microbiota and inflammation in osteonecrosis of the jaw

Carmen Vidal Real¹, Mario Pérez Sayáns², José M Suárez Peñaranda³, Fernanda Pardo Sanchez⁴, Pilar Gándara Vila¹, Andrés Blanco Carrión¹, Alberto Rodríguez Archilla⁵, Abel García García²

¹Oral Medicine, Oral Surgery and Implantology Unit, Faculty of Medicine and Dentistry, Enterríos s/n, Santiago de Compostela C.P. 15782 Spain; ²Oral Medicine, Oral Surgery and Implantology Unit, Faculty of Medicine and Dentistry, Instituto de Investigación Sanitaria de Santiago (IDIS), Santiago de Compostela, Spain, Enterríos s/n, Santiago de Compostela C.P. 15782 Spain; ³Departments of ³Pathology and Forensic Sciences, ⁴Microbiology, University Hospital and School of Medicine of Santiago de Compostela, Enterríos s/n, Santiago de Compostela C.P. 15782 Spain; ⁵Faculty of Dentistry, University of Granada, Colegio Maximo s/n, Campus Universitario de Cartuja, E-18071 Granada, Spain

Received December 11, 2015; Accepted February 18, 2016; Epub April 1, 2016; Published April 15, 2016

Abstract: Background: Describe the presence of Actinomyces in bone biopsies and exudates from patients with ONJ and to determine the degree of inflammation caused by it, evaluating its relationship with clinical/pathological parameters and prognosis as regards evolution of the patient according to the antibiogram for the sample. Material and methods: 28 patients with ONJ were reviewed retrospectively. Wound exudate was submitted to microbiology analyses and antibiogram. Bone sequestra biopsies were analyzed histopathologically to visualize the Actinomyces colonies. Results: 87.5% of biopsies showed the presence of Actinomyces. The inflammatory response was very variable, ranging from absent to intense but it increases with age (P=0.005). Aerobic bacteria were found almost exclusively in patients with grade I and II ONJ (85%). In contrast, anaerobic bacteria were present in 56% of patients for all three grades of ONJ. The combination of amoxicillin with clavulanic acid showed good sensitivity in the majority of patients (82.6%). Conclusions: The degree of inflammation does not appear to be correlated to the density of Actinomyces colonies observed histologically. Elderly patients had greater inflammation and worse response to treatment. The combination of amoxicillin with clavulanic acid gave the best results. It is essential to prioritize both prevention and assessing the risk factors.

Keywords: Osteonecrosis of the jaw, bisphosphonate, radiotherapy, actinomyces, inflammation

Introduction

Osteonecrosis of the jaw (ONJ) is one of the worst complications for patients under bisphosphonate treatments or head and neck radiotherapy. Its etiopathogenesis is unclear, but the presence of microflora in the oral cavity may be one of the factors responsible for initiating or promoting the osteonecrosis of the jaw (ONJ). Indeed, both biopsies and bone sequestra have shown the presence of bacteria such as *Fusobacterium*, *Eikenella*, *Bacillus*, *Actinomyces*, *Staphylococcus* and *Streptococcus* [1].

The role of *Actinomyces* has been recently debated, both in terms of when it begins and the progression of the pathology. *Actinomyces* are Gram-positive, non-spore forming and non-acid/alcohol fast bacilli with a tendency to form

filaments. Some species are strictly anaerobic whereas others are facultatively anaerobic. Numerous *Actinomyces* are opportunistic pathogens of the oral cavity and have been found in periodontal pockets, lesions caused by caries and on the surface of the oral mucosa [1].

Although *Actinomyces* does not cause disease in the presence of intact mucosa, when mucosal integrity is lost as a result of trauma, surgery or infection, and it reaches the jaw bone it can behave as a pathogen and initiate a chronic inflammatory process that leads to tissue destruction and osteolysis [2, 3].

Oral/cervicofacial actinomycosis is the most common, accounting for up to 55% of cases in several series, with *Actinomyces israelii* being the most common pathogenic agent [4]. It can

appear as acute forms, with suppuration of the soft tissue, or as chronic forms in which indurated inflammation with multiple fistulas or twisting trajectories are observed. The latter usually require antibiotic treatment over several months and prognosis is uncertain [4-6].

The presence of *Actinomyces* is related to bisphosphonate-associated osteonecrosis of the jaw and osteomyelitis, although it remains unclear whether it represents a key factor in the pathogenesis of these diseases [7, 8]. The aim of this study is to describe the presence of *Actinomyces* in bone biopsies and exudates from patients with ONJ and to determine the degree of inflammation caused by it, evaluating its relationship with clinical/pathological parameters and prognosis as regards evolution of the patient according to the antibiogram for the sample.

Materials and methods

The medical records for 28 adult patients (16 males and 12 females) with a mean age of 71.96 years attended by the Oncology Department at the Complejo Hospitalario Universitario de Santiago de Compostela (C.H.U.S.) were reviewed retrospectively. All patients were referred to the specialized Oral Surgery and Implantology Unit at the School of Medicine and Dentistry in Santiago de Compostela for dental assessment prior to treatment and follow-up of possible complications resulting from such treatment. This is a retrospective study and is exempt of IRB approval.

Patients with osteonecrosis of the jaws who had undergone oral or intravenous bisphosphonate treatments were included, as well as those subject to head and neck radiotherapy over an eight-year period (2006-2014). The diagnostic criteria of the ONJ in patients undergoing bisphosphonate therapy was described by The American Association of Oral and Maxillofacial Surgeons (AAOMS) [9]; while in the case of head and neck radiotherapy patients, only those who had bone exposure of over eight weeks of evolution were considered [10].

The variables collected included underlying disease, clinical findings, type and duration of bisphosphonate therapy, histological and radiological findings, bacteriological cultures and treatment. Osteonecrosis was classified on the basis of the degree of involvement according to

Bagán [11] et al. Grade I: Asymptomatic, with exposed bone or intraoral fistula; grade II: Symptomatic, with exposed bone or intraoral fistula; grade III: Fracture, infection, dental involvement, osteolysis with involvement of the lower edge of the jaw or communication with the maxillary sinus.

Wound exudate samples from the region of exposed bone were submitted for Gram staining and cultured in liquid medium (thioglycolate broth) and solid media (blood agar and chocolate agar for aerobic bacterial growth, Sabouraud agar for yeast growth and Schaedler agar for anaerobic bacterial growth). Cultured plates were incubated for 48 hours at 37°C under a CO₂ atmosphere and for 72 hours in anaerobiosis chambers. Microorganisms were identified using the Vitek 2 (Bio-Merieux, Marcy l'Etoile, France) and Microscam systems (Siemens, Erlangen, Germany) in the case of aerobes and API-ANA (Biomeriex) in the case of anaerobes. The antimicrobial susceptibility tests were performed using the e-test method (AB biodisk) and followed the interpretation criteria of the Clinical Laboratory Standards Institute (CLSI).

Bone sequestra biopsies were fixed in 10% buffered formalin and embedded in paraffin according to standard procedures. For evaluation, they were stained with hematoxylin/eosin, PAS and methenamine silver to visualize the *Actinomyces* colonies. The presence of these colonies was evaluated semi-quantitatively as scarce (only isolated colonies), very abundant (present in every high power field) and moderately abundant (for cases that do not fulfill the previous requirements). In addition, the presence of acute inflammation, estimated by the amount of polymorphonuclear neutrophils (PMN) present in the specimen, was also quantified into three categories (mild when only a few PMNs were present, moderate, when they were present in small groups, and intense, when they were seen in every microscopic field in the histopathological study). Finally, chronic inflammation (indicated by the presence of lymphocytes and/or plasma cells) was also recorded.

All data obtained were analyzed using SPSS version 20.0 for Windows. The discontinuous or discrete quantitative variables were analyzed using descriptive statistics, with the results being expressed as mean, standard deviation, and as frequency tables and percentages for

Microbiota and inflammation in ONJ

Table 1. Relationship between the quantity of Actinomyces and the inflammatory response

Grade	Actinomyces				Inflammation				
	Null	Mild	Moderate	Abundant	Null	Scarce	Moderate	Abundant	Chronic
I	0 (0%)	0 (0%)	0 (0%)	2 (8.3%)	2 (8.3%)	0 (0%)	0 (0%)	0 (0%)	0 (0%)
II	0 (0%)	2 (8.3%)	8 (33.3%)	7 (29.1%)	8 (33.3%)	1 (4.1%)	4 (16.6%)	2 (8.3%)	1 (4.1%)
III	1 (4.2%)	1 (4.2%)	3 (12.5%)	0 (0%)	3 (12.5%)	1 (4.1%)	1 (4.2%)	0 (0%)	1 (4.1%)
Total	1 (4.2%)	3 (12.5%)	11 (45.8%)	9 (37.5%)	13 (54.2%)	2 (8.3%)	5 (20.8%)	2 (8.3%)	2 (8.3%)

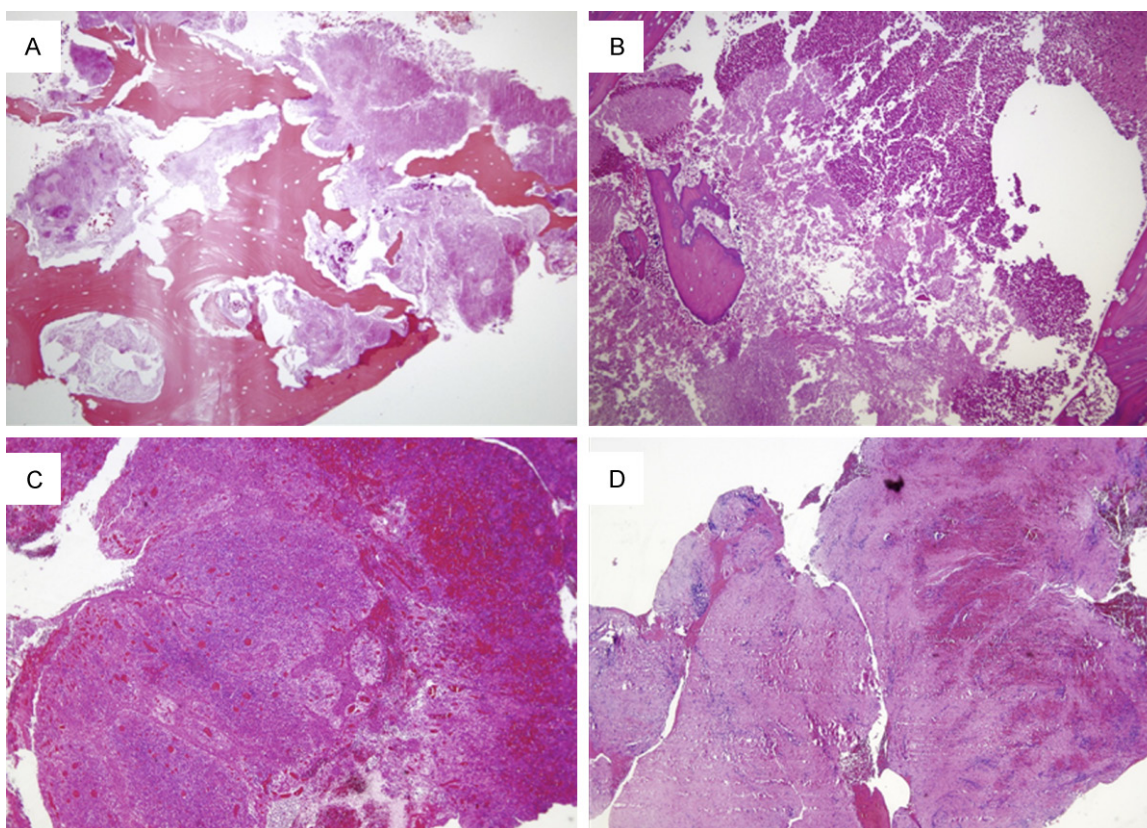


Figure 1. Histopathological examination revealed different combinations of Actinomyces and inflammatory response. Some cases demonstrated abundant Actinomyces colonies but lacked any inflammatory infiltration (A), while in other examples; this microorganism was identified along with a dense infiltrate of PMNs (B). PMNs were also seen in some cases in absence of Actinomyces (C). Finally in some patients the only change consisted in fibrosis and scant inflammatory response composed mainly of lymphocytes (D).

qualitative variables. The chi-squared test, Student's t-test, or a one-way ANOVA were used during intervariable relationship studies, depending on the application conditions. *P* Values ≤ 0.05 were considered to be statistically significant.

Results

Clinical findings

Of the 28 patients, 16 were men (57.1%) and 12 were women (48.8%), with an average age of 71.96 years (SD 8.94). According to the reg-

istered systemic risk, 8 patients (28.5%) were diabetic, 15 (53.6%) were undergoing chemotherapy, four (14.3%) were smokers, 14 (50%) were hypertensive and nine (32.1%) were taking corticosteroids. The reason for bisphosphonate treatment was oral cancer (14.3%), breast cancer (25%), prostate cancer (39.2%), multiple myeloma (10.7%) and osteoporosis (10.7%).

The region of the oral cavity most affected by osteonecrosis was the lower jaw (67.8%), followed by the upper jaw (21.4%) and both jaws (10.7%).

Microbiota and inflammation in ONJ

Table 2. Relationship between grade of ONJ and quantity of Actinomyces and the type and degree of inflammation

Actinomyces	Inflammation				
	Null	Mild	Moderate	Abundant	Chronic
Null	0	0	1	0	0
Scarce	1	0	1	0	1
Moderate	8	1	1	0	1
Abundant	4	1	2	2	0

Table 3. Relationship between the types of bacterium isolated and grade of ONJ

	Grade	Grade	Grade	P value
	I	II	III	
Staphylococcus sp	0	1	1	0.372
Capnocytophaga sp	2	1	0	0.008
Morganella morganii	0	1	0	0.817
Enterobacter cloacae	0	1	2	0.037
Streptococcus sp	3	12	1	0.112
Eikenella corrodens	0	3	1	0.664
Neisseria sp	3	3	0	0.004
Proteus sp	0	1	0	0.074
Actinomyces sp	2	3	0	0.003
Veionella parvula	0	0	2	0.817
Peptoestreptococcus sp	0	3	0	0.515
Fusobacterium sp	0	1	1	0.372
Prevotella sp	0	4	1	0.648
Bacteoides sp	0	2	0	0.655

The degree of the lesions was variable, depending on the type of treatment administered. Patients receiving intravenous bisphosphonate treatment presented all grades of ONJ, whereas those receiving oral bisphosphonates only presented grade II. Patients treated with radiotherapy exhibited more severe grade II (5%) and grade III (75%) lesions.

Histological findings

Histopathological study was performed in 24 of the 28 patients. Of these, 21 (87.5%) showed the presence of Actinomyces. The pathogen count was very abundant in grades I and II, whereas patients in grade III presented lower quantities of Actinomyces (**Table 1**).

Presence of Actinomyces was not associated with any sign of inflammation in 13 patients (54.2%) but it was found that the inflammatory response triggered by the presence of Acti-

nomyces was very variable, ranging from absent to intense (**Figure 1A** and **1B**; **Table 1**).

Acute inflammation was present in 37.5% of patients and was quantified as mild (2 patients), moderate (5 patients) and abundant (2 patients), with the latter two being present in patients with grade II osteonecrosis only. In the remaining cases the intensity of inflammation was found to increase with age, with the mean age for absence of inflammation (65.31; SD: 7.91) being lower than that for abundant inflammation (81.00; SD: 2.83) (**Figure 1B** and **1C**). These differences were statistically significant ($F=5.270$, $P=0.005$). Finally, there were only two cases of chronic inflammation, one in a patient with grade II ONJ and the other in a patient with grade III ONJ (**Table 2**).

Microbiological findings

All bacteria isolated in cultures were recorded (**Table 3**). Aerobic bacteria were found almost exclusively in patients with grade I and II ONJ (85%), with this value being statistically significant. In contrast, anaerobic bacteria were present in 56% of patients for all three grades of ONJ. Although all cases with grade III ONJ presented anaerobic bacteria, this finding was not statistically significant.

Except for *Streptococcus* sp., which was highly abundant in grade II ONJ, the families of bacterial species specific to the different grades of osteonecrosis did not differ significantly. Only three bacteria exhibited statistically significant differences as regards the grades of ONJ (**Table 3**; **Figure 2**).

Antibiograms were also performed for each species detected in order to guide the subsequent antibiotic treatment for these patients. The six antibiotics most commonly used in standard practice were studied and a variable bacterial behavior was observed between ONJ patients.

Penicillin G did not exhibit complete sensitivity in any patient as regards all the bacteria isolated in the cultures. Indeed, this antibiotic exhibited a marked inter-patient variability in terms of response (**Figure 3**).

The combination of amoxicillin with clavulanic acid showed good sensitivity in the majority of

Microbiota and inflammation in ONJ

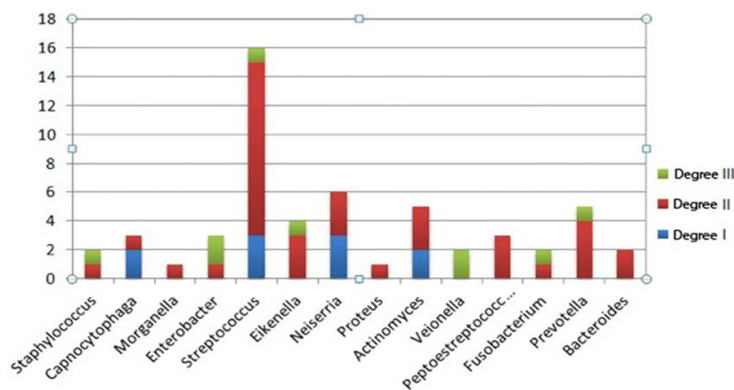


Figure 2. Families of bacterial species specific to the different grades of osteonecrosis.

patients (82.6%), although this finding was not statistically significant (**Figure 4**).

Clindamycin was effective in 40% of patients and resistant in 14.5%, with 28% of patient showing a variable response to this antibiotic. Azithromycin was effective in very few patients (38%) and, moreover, the response was highly variable, with complete sensitivity against the bacteria isolated not being demonstrated (**Figure 5**).

Levofloxacin was effective in 42.8% of patients, the majority of whom showed a good sensitivity (88.8%). Finally, another antibiotic that tends to be used much less in daily practice, namely gentamicin, showed good sensitivity despite being effective in only a few patients (38%).

Discussion

Osteonecrosis of the jaw is currently one of the most important complications in patients receiving bisphosphonate treatment or radiotherapy of the head and neck. However, despite the extensive literature on this subject, there is still no agreement regarding its etiology and treatment. Of the different risk factors described, the presence of microflora in the oral cavity has been recently considered as a potential trigger or stimulating factor in the progress of ONJ. Nevertheless, this view is strongly questioned by other authors. Biopsies and cultures of ONJ lesions have demonstrated the presence of different bacterial species such as *Fusobacterium*, *Eikenella*, *Bacillus*, *Actinomyces*, *Staphylococcus* and *Streptococcus* [12-15]. Although some of these bacteria were con-

centage of patients with *Actinomyces* was intermediate between the values reported by Anavi-Lev et al. [18], who found 100% of patients with *Actinomyces*, and the 86% reported by Schipmann et al. [17]. In contrast, the degree of inflammation does not appear to be correlated to the density of *Actinomyces* colonies observed histologically, and in some cases their presence does not trigger any type of appreciable inflammatory response. This suggests that *Actinomyces* is simply one amongst

considered to be biofilm colonisers rather than invasive pathogens, no study has yet confirmed the importance of oral microflora in the context of ONJ.

Only one study has evaluated the importance of bacterial flora in the beginning and development of ONJ. Mawardi et al. showed that mice infected with *Fusobacterium* after tooth extraction exhibited a higher incidence of bone exposure and infection and, moreover, were more resistant to antibiotherapy [16].

Numerous aerobic and anaerobic microorganisms were isolated from the microbiological cultures of bone exposures taken from our patients. In this respect, it is important to highlight the fact that we found significant differences as regards the type of bacteria present in ONJ samples depending on the grade of lesion. Thus, aerobic bacteria were more abundant in milder (grade I and II) lesions, whereas anaerobic bacteria were isolated in the more advanced cases. This could explain the more difficult recovery of patients with grade III ONJ when following the same therapeutic regimen as in the initial stages. Nevertheless, when genera are taken into account, only three families of bacteria were found to be specific within the different grades of ONJ. Thus, *Capnocytophaga* sp, *Neisseria* sp and *Actinomyces* sp exhibited significant differences related to the degree of involvement of ONJ (**Table 3**).

In our series, 87.5% of patients with a bone sequestrum biopsy had a histological finding of *Actinomyces* in the bone, a figure coincidental with of previous reports [17, 18]. Thus, the per-

Microbiota and inflammation in ONJ

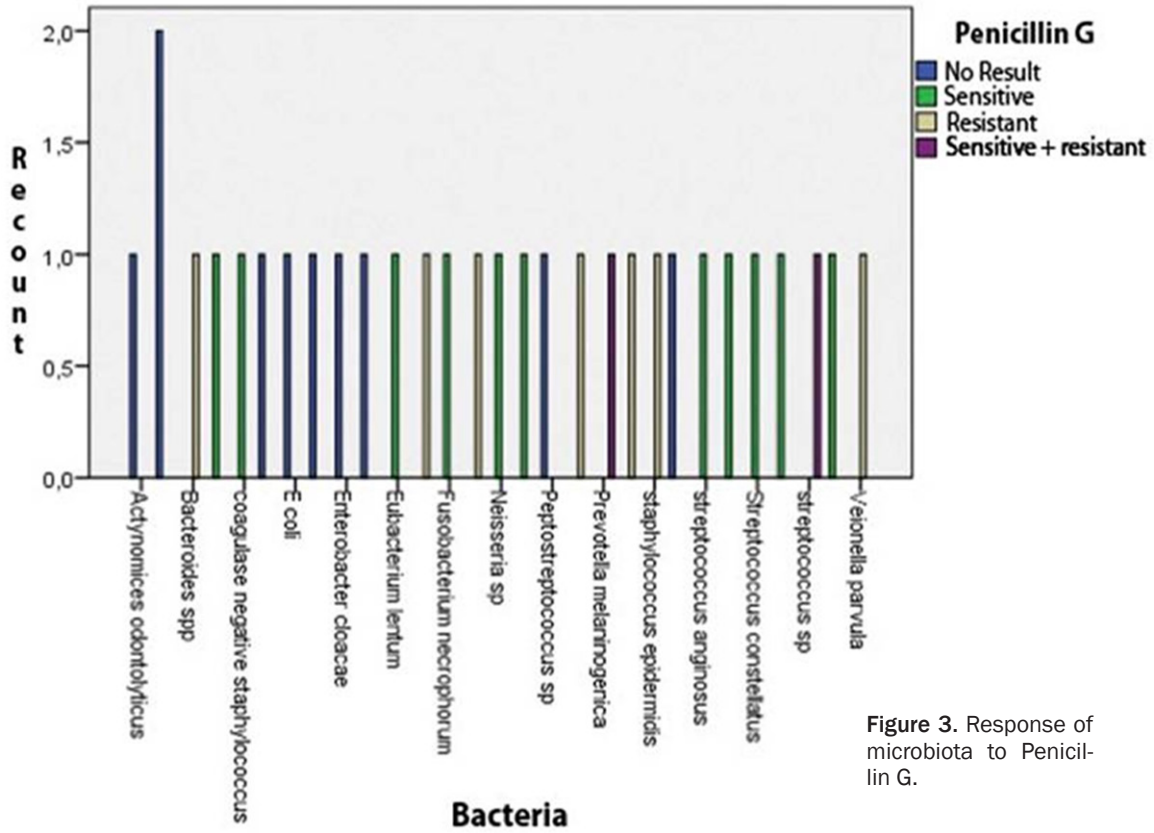


Figure 3. Response of microbiota to Penicillin G.

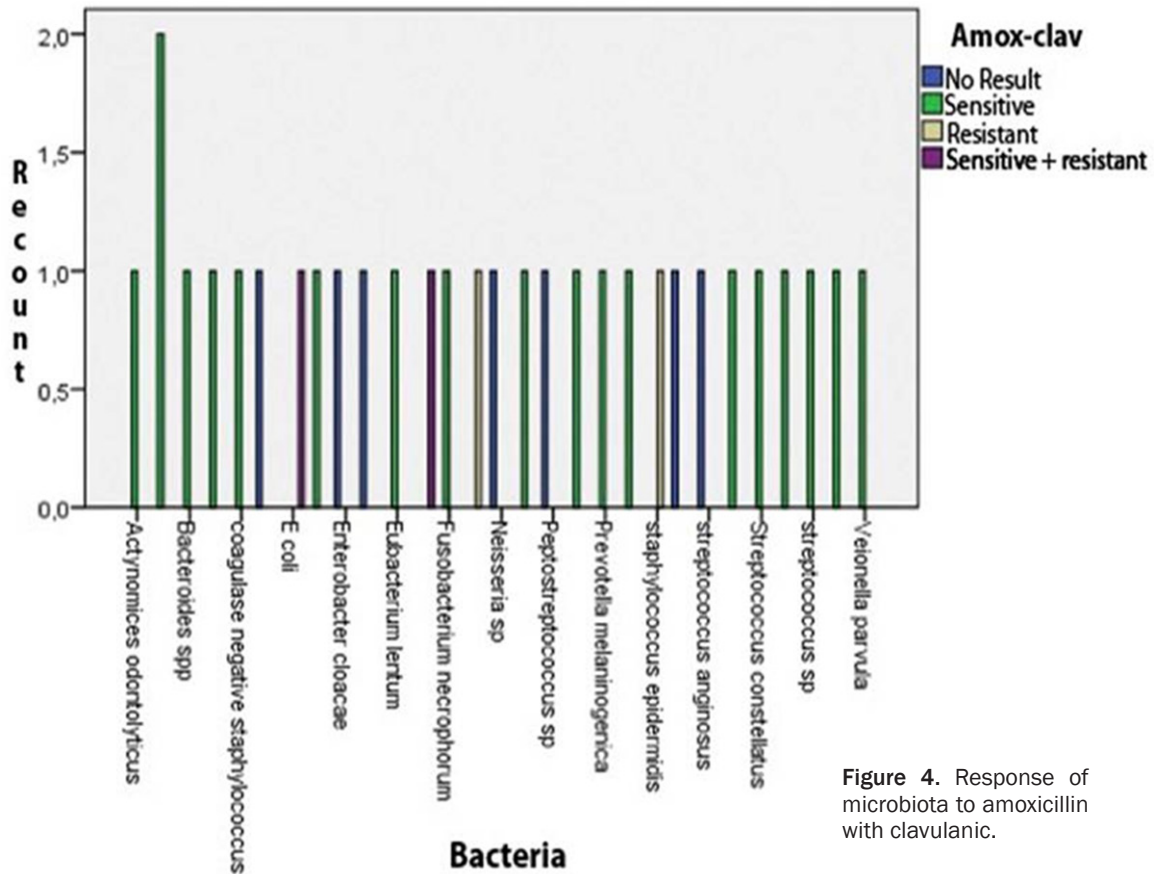


Figure 4. Response of microbiota to amoxicillin with clavulanic.

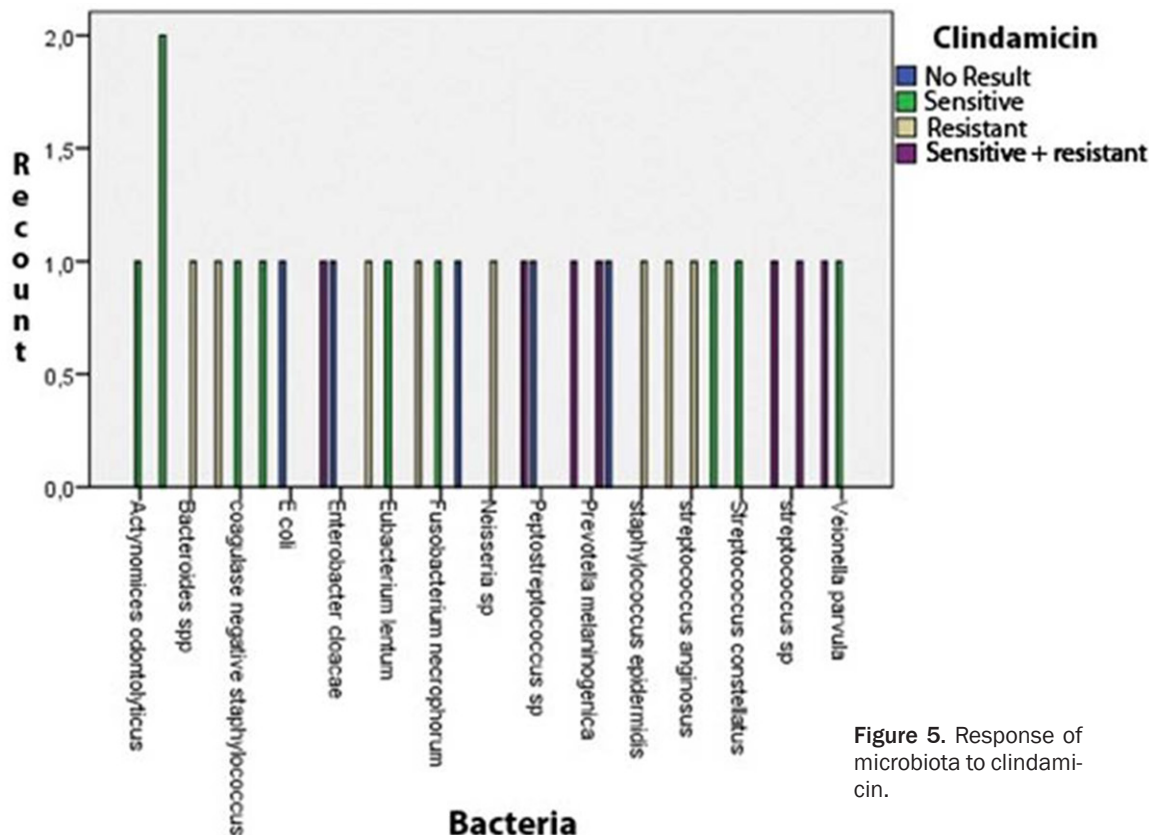


Figure 5. Response of microbiota to clindamycin.

many microorganisms in the microflora and that its role as an isolated pathogen remains unclear.

A fact clearly stated in the literature is the improvement of lesions with different antibiotic regimens. Thus, the study by Kaplan et al. [19] showed Actinomyces in lesions, which led the authors to recommend treatment with wide range antibiotics for long periods of time (between 3 and 6 months). Biasotto et al. [20] showed that treatment for shorter periods led to relapse in patients. The retrospective study of Marx et al. [21] showed that 90% remained pain-free after receiving oral penicillin VK (500 mg 4 times a day) and 0.12% chlorhexidine as a mouthwash for at least one year. Finally, the study by Naik et al. [22] coincides with the previous proposals by recommending a prolonged antibiotic regimen, in this case intravenous for 2-6 weeks followed by oral treatment for 6-12 months in the most severe cases. Moreover, these authors recommend debriding the necrotic tissue and bone sequestra if possible.

In our series, despite that the antibiotic treatment was variable, the majority of patients

improved after antibiotic treatment for periods of 2-4 weeks along with antimicrobial treatment (0.12% chlorhexidine). It should be noted, however, that the antibiograms showed resistance to penicillin G and little activity with clindamycin, azithromycin and levofloxacin, and that the combination of amoxicillin with clavulanic acid gave the best results.

Conclusions

The degree of inflammation does not appear to be correlated to the density of Actinomyces colonies observed histologically, and in some cases their presence does not trigger any type of appreciable inflammatory response. In light of the results obtained and taking into account the relationship between age and degree of inflammation, elderly patients had greater inflammation and worse response to treatment due to possible immunosuppression, conditioned by age and the pharmacological interactions typical to polymedicated patients. Although the different treatments proposed by the authors, the combination of amoxicillin with clavulanic acid gave the best results. A new option of treatment combining intravenous and oral antibiotic administration for longer periods

of time has been proposed; further standardized studies are still required. As the etiology of ONJ remains unknown, it is essential to prioritize both prevention, assessing the risk factors presence, and subsequent treatment of this disease. According to the literature, and in our experience, the bacterial component is a very important factor as regards the development and cure of ONJ; therefore we believe that antibiotic treatment can markedly improve the evolution of these patients provided it is combined with strict local control using bactericidal antiseptics such as chlorhexidine.

Disclosure of conflict of interest

None.

Address correspondence to: Mario Pérez Sayáns, Oral Medicine, Oral Surgery and Implantology Unit, Faculty of Medicine and Dentistry, Instituto de Investigación Sanitaria de Santiago (IDIS), Santiago de Compostela, Spain, Entrerriós s/n, Santiago de Compostela C.P. 15782 Spain. Tel: 00346262335-04; Fax: 0034986295424; E-mail: perezsayans@gmail.com

References

- [1] Mawardi H, Giro G and Kajiya M. A role of oral bacteria in bisphosphonate-induced osteonecrosis of the jaw. *J Dent Res* 2011; 90: 1339-1345.
- [2] Murray PR, Rosenthal KS, Kobayashi GS and Pfaller MA. A textbook of medical microbiology. 4th edition. St. Louis: Mosby; 2002. pp. 334-60.
- [3] Pulverer G, Schutt-Gerowitt H and Schaal KP. Human cervicofacial actinomycoses: Microbiological data for 1997 cases. *Clin Infect Dis* 2003; 37: 490-497.
- [4] Miller M and Haddad AJ. Cervicofacial actinomycosis. *Oral Surg Oral Med Oral Pathol Oral Radiol Endod* 1998; 85: 496-508.
- [5] Greenberg MS GM. Burket's oral medicine diagnosis and treatment. 10th edition. Hamilton (Ontario): Decker; 2003. pp. 176-7.
- [6] Nagler R, Peled M and Laufer D. Cervicofacial actinomycosis: A diagnostic challenge. *Oral Surg Oral Med Oral Pathol Oral Radiol Endod* 1997; 83: 652-656.
- [7] Parfitt AM. Bone histomorphometry: Techniques and interpretation. In: Recker RR, editor. The physiologic and clinical significance of bone histomorphometric data. Boca Raton (FL): CRC Press; 1983. pp. 143-224.
- [8] Dalle Carbonare L, Valenti MT and Bertoldo F. Bone microarchitecture evaluated by histomorphometry. *Micron* 2005; 36: 609-616.
- [9] Advisory Task Force on Bisphosphonate-Related Osteonecrosis of the Jaws, American Association of Oral and Maxillofacial Surgeons. American association of oral and maxillofacial surgeons position paper on bisphosphonate-related osteonecrosis of the jaws. *J Oral Maxillofac Surg* 2007; 65: 369-376.
- [10] Schwartz HC and Kagan AR. Osteoradionecrosis of the mandible: Scientific basis for clinical staging. *Am J Clin Oncol* 2002; 25: 168-171.
- [11] Bagan J, Scully C, Sabater V and Jimenez Y. Osteonecrosis of the jaws in patients treated with intravenous bisphosphonates (BRONJ): A concise update. *Oral Oncol* 2009; 45: 551-554.
- [12] Marx RE, Sawatari Y, Fortin M and Broumand V. Bisphosphonate-induced exposed bone (osteonecrosis/osteopetrosis) of the jaws: Risk factors, recognition, prevention, and treatment. *J Oral Maxillofac Surg* 2005; 63: 1567-1575.
- [13] Hansen T, Kunkel M, Weber A and James Kirkpatrick C. Osteonecrosis of the jaws in patients treated with bisphosphonates-histomorphologic analysis in comparison with infected osteoradionecrosis. *J Oral Pathol Med* 2006; 35: 155-160.
- [14] Hansen T, Kunkel M and Springer E. Actinomycosis of the jaws-histopathological study of 45 patients shows significant involvement in bisphosphonate-associated osteonecrosis and infected osteoradionecrosis. *Virchows Arch* 2007; 451: 1009-1017.
- [15] edghizadeh PP, Kumar SK, Gorur A, Schaudinn C, Shuler CF and Costerton JW. Identification of microbial biofilms in osteonecrosis of the jaws secondary to bisphosphonate therapy. *J Oral Maxillofac Surg* 2008; 66: 767-775.
- [16] Mawardi H, Giro G and Kajiya M. A role of oral bacteria in bisphosphonate-induced osteonecrosis of the jaw. *J Dent Res* 2011; 90: 1339-1345.
- [17] Schipmann S, Metzler P and Rossle M. Osteopathology associated with bone resorption inhibitors - which role does actinomyces play? A presentation of 51 cases with systematic review of the literature. *J Oral Pathol Med* 2013; 42: 587-593.
- [18] Anavi-Lev K, Anavi Y, Chaushu G, Alon DM, Gal G and Kaplan I. Bisphosphonate related osteonecrosis of the jaws: Clinico-pathological investigation and histomorphometric analysis. *Oral Surg Oral Med Oral Pathol Oral Radiol* 2013; 115: 660-666.
- [19] Kaplan I, Anavi K and Anavi Y. The clinical spectrum of actinomyces-associated lesions of the oral mucosa and jawbones: Correlations with histomorphometric analysis. *Oral Surg Oral Med Oral Pathol Oral Radiol Endod* 2009; 108: 738-746.
- [20] Biasotto M, Chiandussi S and Dore F. Clinical aspects and management of bisphospho-

Microbiota and inflammation in ONJ

- nates-associated osteonecrosis of the jaws. *Acta Odontol Scand* 2006; 64: 348-354.
- [21] Marx RE. Reconstruction of defects caused by bisphosphonate-induced osteonecrosis of the jaws. *J Oral Maxillofac Surg* 2009; 67: 107-119.
- [22] Naik NH and Russo TA. Bisphosphonate-related osteonecrosis of the jaw: The role of actinomyces. *Clin Infect Dis* 2009; 49: 1729-1732.