

Expression of the p53 protein in oral squamous cell carcinomas associated with Epstein-Barr virus

Miguel Angel González-Moles^{1*}, Pablo Galindo², Jose Gutierrez³,
Alberto Rodríguez-Archilla¹, Isabel Ruiz-Avila⁴, and Elena Sanchez-Fernandez²

¹Department of Oral Medicine, and ²Department of Oral Surgery, School of Dentistry, University of Granada, Granada, Spain, ³Department of Microbiology, School of Medicine, University of Granada, Granada, Spain, and ⁴Department of Pathology, Jaen General Hospital, Granada, Spain (*Reprint address)

Key words: Epstein-Barr virus, oral squamous cell carcinoma, p53 protein

Abstract


The behaviour of the p53 protein has been investigated in some human carcinomas associated with Epstein-Barr virus (EBV) but not in EBV-positive oral squamous cell carcinomas (OSCC). The present study aimed to compare the p53 protein expression in EBV-positive OSCC with that in EBV-negative OSCC. The cases had been gathered in a study previously published. An immunohistochemical technique with BP53-12 monoclonal antibody was applied on 74 of the 107 OSCC from the earlier work. The nuclear or cytoplasmic expression of the p53 protein was classified as, absent (0% of neoplastic cells positive), mild (<25% positive), moderate (25–30% positive), or extensive (>50% positive). The p53 protein was expressed by 60.8% of the OSCC. Out of the fourteen EBV-positive OSCC, 57.1% (8 cases) expressed p53, always in the nucleus and never in the cytoplasm. Of the 60 EBV-negative OSCC, 61.6% (37 cases) expressed the p53 protein. Of 37 cases 33 (89.1%) showed nuclear expression of p53 and nineteen cases (51.3%) revealed cytoplasmic expression. There was a statistically significant inverse correlation between cytoplasmic expression of the p53 protein and the presence of EBV DNA ($p < 0.01$). Thus, the EBV-positive tumours less frequently expressed p53 in the cytoplasm. No evidence of an accumulation of the p53 protein in OSCC associated with EBV was recorded.

Introduction

The most commonly documented genetic alterations which appear in human cancer are those which occur in the short arm of chromosome 17 (17P) in the region which contains the *p53* gene (Nigro *et al.*, 1989; Hollstein *et al.*, 1991). The p53 protein is a tumour suppressor with a molecular weight of 53 kD. It can block the cell cycle at the late G₁ phase in cells which carry sublethal damage in their genome until their complete repair. Otherwise it can induce apoptosis, thus avoiding the development of cell clones with severe DNA damage (Cordon-Cardo, 1995). Mutations of the *p53* gene give rise to a mutated p53 protein which has lost its function as genome guardian (Lane, 1992) and permits the survival of DNA-damaged cells. Nevertheless, some cellular events which do not involve *p53* gene mutation can alter the function of the wild-type p53 protein, leading to

147 *Microbios* 102 147–154 2000

Published and © 2000 by The Faculty Press
88 Regent Street, Cambridge, Great Britain



a similar outcome. Some DNA virus proteins interact with the p53 protein and inactivate it, including the large T antigen of SV40 virus (Ludlow, 1993), E1A of adenovirus (Frank *et al.*, 1994), E1B of adenovirus (Moran, 1993) and E6 and E7 proteins of human papillomavirus (Vousden, 1993; Field, 1992).

The EBV is a ubiquitous DNA virus which associates with some neoplasias, among other diseases, including African Burkitt's lymphoma, nasopharyngeal carcinoma and gastric carcinoma (Baskin *et al.*, 1995). Our group recently published the appearance of EBV DNA in a series of OSCC (González-Moles *et al.*, 1998). The behaviour of the p53 protein in human carcinomas associated with EBV has been studied in gastric carcinoma, salivary gland carcinoma (Leung *et al.*, 1998; Nagao *et al.*, 1996), sinus carcinoma, middle ear carcinoma, lachrymal carcinoma and tonsillar carcinoma (Leung *et al.*, 1998). Research on p53 status in cases associated with EBV indicates an over-regulation of p53 through an unknown viral mechanism. However, to our knowledge there has been no analysis of the behaviour of the p53 protein in EBV-positive OSCC.

The present study aimed to compare the expression of the p53 protein in EBV-positive OSCC with that in EBV-negative OSCC, by analysing cases previously studied by our group (González-Moles *et al.*, 1998).

Materials and methods

An immunohistochemical technique was applied to tissue sections 3–5 µm thick of operative specimens from primary tumours of patients treated for OSCC at our hospital. A study on this series was previously published by us (González-Moles *et al.*, 1998), and included 107 tumours, 17.59% of which (19 cases) were EBV-positive. Immunohistochemistry could only be used on 74 cases in the present work, since the tumour tissue in the paraffin block was inadequate in the remaining 35 cases. Of the 74 cases analysed immunohistochemically, we knew *a priori* that 19.2% (15 cases) were EBV-positive.

After deparaffinization and dehydration, the endogenous peroxidase was blocked by incubation for 30 min in 0.3% H₂O₂ in methanol. Nonspecific binding was inhibited by incubation with 1:20 dilution of normal horse serum for 60 min. Sections were incubated at 1:50 and 1:100 dilution of monoclonal anti-p53 protein with antibody Bp53-12 overnight at 41°C in a humidified chamber. Biotinylated

anti-mouse IgG (Vector Lab., U.S.A.) was applied at a dilution of 1:200 for 30 min, followed by streptavidin peroxidase (Vector Lab., U.S.A.) at 1:100 for an additional 30 min. Finally, the peroxidase activity was developed by the 3,3'-diaminobenzidine hydrogen peroxidase reaction. Primary antibody replaced by normal goat serum, and a known p53-positive squamous cell carcinoma, were used for negative and positive controls, respectively. Antigen retrieval methods were used in this investigation. The results of the immunoreactivity were evaluated and classified according to the cytoplasmic and nuclear reactions observed. The nuclear and cytoplasmic staining of p53 was assessed and considered positive when an intense brown colour appeared in the nucleus or cytoplasm of the neoplastic cells. The extension of the p53 protein expression was classified as absent (0% of neoplastic cells positive), mild (<25% positive), moderate (25–30% positive), or extensive (>50% positive).

The means, standard deviations (SD) and percentages were calculated. The Chi-squared test was applied for the comparison of qualitative independent distributions. The Spearman non-parametric correlation coefficient was used to compare quantitative, ordinal or dichotomous variables. The data were processed with the SPSS program for Windows 6.01 (SPSS Inc., Chicago, Illinois, U.S.A.) according to Norusis (1993).

Table 1 Expression of the p53 protein in the 74 tumours

Variable	Distribution	n (%)
Nuclear expression	None	33 (44.6)
	Mild	15 (20.3)
	Moderate	12 (16.2)
	Extensive	14 (18.9)
Cytoplasmic expression	None	55 (74.3)
	Mild	1 (1.4)
	Moderate	6 (8.1)
	Extensive	12 (16.2)

Results

We observed that 60.8% of the 74 OSCC analysed expressed the p53 protein. The nuclear and cytoplasmic expressions of p53 in the series are listed in Table 1 (Figures 1 and 2). Of the fourteen EBV-positive OSCC, 51% (eight cases) expressed p53, always in the nucleus and never in the cytoplasm. EBV-negative OSCC expressed the p53 protein (37/60 cases or 61.6%), and 33/37 (89.1%) were in the nucleus with 19/37 (51.3%) in the cytoplasm. The only statistically significant finding was an inverse correlation between the cytoplasmic expression of the p53 protein and the presence of EBV DNA ($p < 0.01$). Thus, EBV-positive tumours expressed p53 in the cell cytoplasm with less frequency.

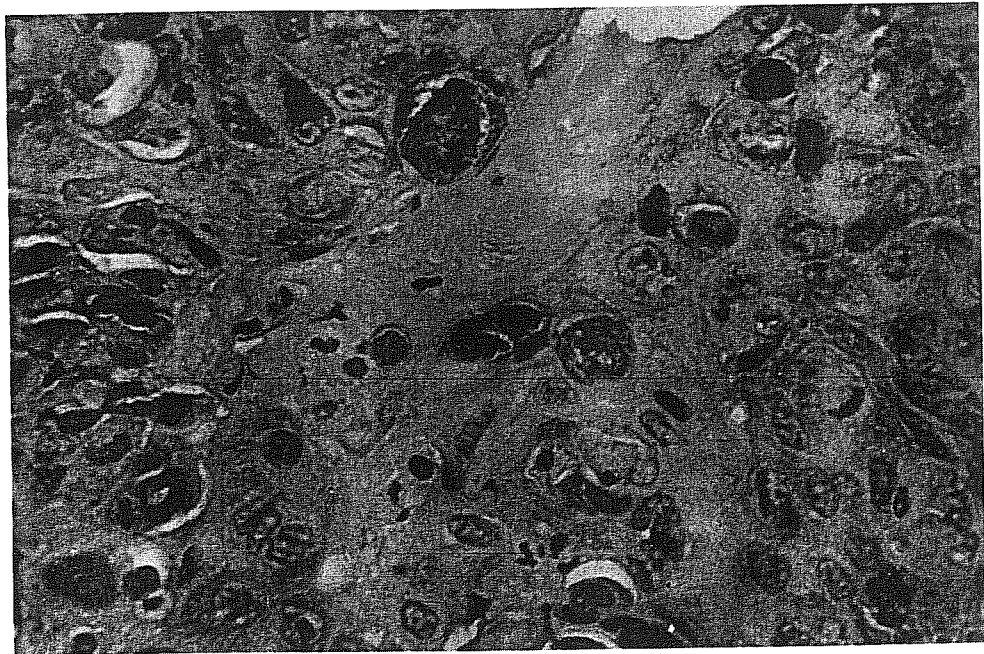
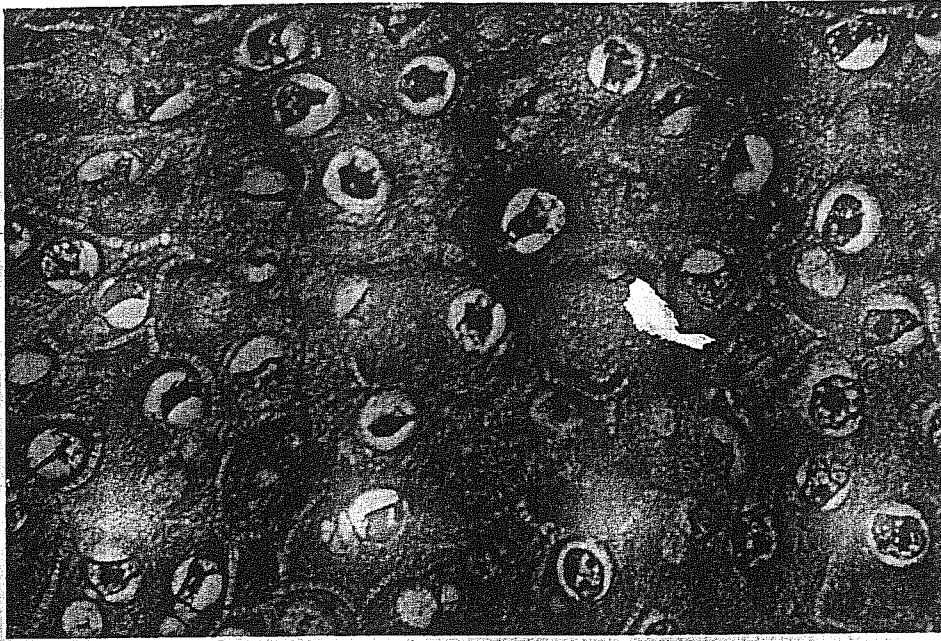


Figure 1 Nuclear expression of the p53 protein in neoplastic cells. Immunohistochemistry (IMH) staining. x40.



7
Figure 2 Cytoplasmic expression of the p53 protein in neoplastic cells. IMH staining. x40.

Discussion

Previous reports by different authors on the behaviour of the p53 protein in EBV-positive tumours at distinct locations have been contradictory. Leung *et al.* (1998) compared gastric and other carcinomas which were EBV-positive with those which were EBV-negative and found significant differences. They proposed a non-mutational mechanism of p53 over-regulation, possibly related to an unknown viral protein implicated in oncogenesis. The up-expression of p53 has also been described by other authors (Niedobitek *et al.*, 1993; Sheu *et al.*, 1994; Sheu *et al.*, 1995) but investigations of the genome have not detected gene mutations (Effert *et al.*, 1992; Lo *et al.*, 1992; Sun *et al.*, 1992; Spruck *et al.*, 1992; Nasrin *et al.*, 1994), suggesting a stabilization of the protein through a viral mechanism (Leung *et al.*, 1998).

Gulley *et al.* (1996) studied nasopharyngeal carcinomas and found a significant association between the expression of the viral product EBV-1 and the accumulation of the p53 protein. This association may reflect the accumulation of wild-type protein being physiologically over-regulated in response to an invader (Gulley *et al.*, 1998). Zhang *et al.* (1994) stated that p53-expressing cells were selectively protected from acute cell injury produced by the replicative activity of the virus, given that the wild-type (but not the mutated) p53 protein inhibited the viral replicative cycle and promoted viral latency.

Finally, it cannot be ruled out that accumulated p53 protein is in a dysfunctional state as a result of its binding to EBV proteins. This possibility is based on laboratory studies which identified two EBV proteins (BZLF1 and EBNA5) able to bind to p53 (Szekely *et al.*, 1993). EBNA5 probably plays the least important pathogenic role, since it has not been detected in nasopharyngeal carcinomas, in which BZLF1 is frequently expressed (Martel-Renoir *et al.*, 1995; Yip *et al.*, 1994). Furthermore, *in vitro* studies have demonstrated that BZLF1 protein not only binds to but also inactivates the p53 protein (Zhang *et al.*, 1994). Other researchers have suggested the possibility that the nuclear 2 antigen of EBV (EBNA2) binds to p53, given that it is structurally homologous to the E7 protein of the human papillomavirus and to E1A of adenovirus, which have been proven to bind to p53 (Spruck *et al.*, 1992; Frank *et al.*, 1994).

However, published results on this issue vary, and Gulley *et al.* (1996) found no significant differences in p53 levels among eleven gastric carcinomas associated with the virus (Gulley *et al.*, 1996). The present work did not reveal any relationship which demonstrated an accumulation of the p53 protein in EBV-associated OSCC cases. On the contrary, tumours which expressed p53 in extensive areas of the cell cytoplasm, a site where p53 could presumably bind to viral proteins, were the most frequently negative for EBV ($p < 0.01$).

Thus, at least for OSCC, the present study does not support the hypothesis that EBV-mediated p53 stabilization is a major mechanism in oral tumorigenesis.

References

- BASKIN G. B., Roberts E. D., Kuebler D., Martin L., Blauw B., Heeney J. and Zurcher C. 1995. Squamous epithelial proliferative lesions associated with rhesus Epstein-Barr virus in simian immunodeficiency virus-infected rhesus monkeys. *J. infect. Dis.* **172** 535-9.
- CORDON-CARDO C. 1995. Mutation of cell cycle regulators. Biological and clinical implications for human neoplasia. *Am. J. Path.* **147** 545-60.

- EFFERT P., McCoy R., Abdel-Hamid M., Flynn K., Zhang Q., Busson P., Tursz T., Liu E. and Raab-Traub N. 1992. Alterations of the *p53* gene in nasopharyngeal carcinoma. *J. Virol.* **66** 3768-75.
- FIELD J. K. 1992. Oncogenes and tumour-suppressor genes in squamous cell carcinoma of the head and neck. *Eur. J. Cancer B. Oral. Oncol.* **28B** 67-76.
- FRANK J. L., Bur M. E., Garb J. L., Kay S., Ware J., Sismanis A. and Neifeld J. P. 1994. P53 tumor suppressor oncogene expression in squamous cell carcinoma of the hypopharynx. *Cancer* **73** 181-6.
- GONZÁLEZ-MOLES M. A., Gutierrez J., Ruiz I., Fernandez J. A., Rodriguez M. and Aneiros J. 1998. Epstein-Barr virus and oral squamous cell carcinoma in patients without HIV infection: viral detection by polymerase chain reaction. *Microbios* **96** 23-31.
- GULLEY M. L., Pulitzer D. R., Eagan P. A. and Schneider B. G. 1996. Epstein-Barr virus infection is an early event in gastric carcinogenesis and is independent of *bcl-2* expression and *p53* accumulation. *Hum. Pathol.* **27** 20-7.
- GULLEY M. L., Burton M. P., Allred D. C., Nicholls J. M., Amin M. B., Ro J. Y. and Schneider B. G. 1998. Epstein-Barr virus infection is associated with *p53* accumulation in nasopharyngeal carcinoma. *Hum. Pathol.* **29** 252-9.
- HOLLSTEIN M., Sidransky D., Vogelstein B. and Harris C. C. 1991. The *p53* mutations in human cancers. *Science* **253** 49-53.
- LANE D. P. 1992. Cancer: *p53*, guardian of the genome. *Nature* **358** 15-6.
- LEUNG S. Y., Chau K. Y., Yuen S. T., Chu K. M., Branicki F. J. and Chung L. P. 1998. P53 overexpression is different in Epstein-Barr virus-associated and Epstein-Barr virus-negative carcinoma. *Histopathology* **33** 311-7.
- LO K. W., Mok C. H., Huang D. P., Liu Y. X., Choi P. H., Lee J. C. and Tsao S. W. 1992. P53 mutation in human nasopharyngeal carcinomas. *Anticancer Res.* **12** 1957-63.
- LUDLOW J. W. 1993. Interactions between SV40 large tumour antigen and the growth suppressor proteins pRB and *p53*. *FASEB J.* **7** 866-71.
- MARTEL-RENOIR D., Grunewald V., Touitou R., Schwaab G. and Joab I. 1995. Qualitative analysis of the expression of Epstein-Barr virus lytic genes in nasopharyngeal carcinomas biopsies. *J. gen. Virol.* **76** 1041-8.
- MORAN E. 1993. Interactions of adenoviral proteins with pRB and *p53*. *FASEB J.* **7** 880-5.
- NAGAO T., Ishida Y., Sugano I., Tajima Y., Matsuzaki O., Hino T., Konno A., Kondo Y. and Nagao K. 1996. Epstein-Barr virus-associated undifferentiated carcinoma with lymphoid stroma of the salivary gland in Japanese patients. Comparison with benign lymphoepithelial lesion. *Cancer* **78** 695-703.
- NASRIN N., Taiba K., Hannan N., Hannan M. and al-Sedairy S. 1994. A molecular study of EBV DNA and *p53* mutations in nasopharyngeal carcinoma of Saudi Arab patients. *Cancer Letters* **82** 189-98.
- NIEDOBITEK G., Agathangelou A., Barber P., Smallman L. A., Yones E. L. and Young L. S. 1993. *p53* overexpression and Epstein-Barr virus infection in undifferentiated and squamous cell nasopharyngeal carcinomas. *J. Pathol.* **170** 457-61.
- NIGRO J. M., Baker S. J., Preisinger A. C., Jessup J. M., Hostetter R. and Cleary K. 1989. Mutations in the *p53* occur in diverse human tumour types. *Nature* **342** 705-8.
- NORUSIS N. 1993. *SPSS for Windows. Release 6.0.* SPSS Inc. Chicago, U.S.A.
- SHEU L. F., Chen A., Tseng H. H., Leu F. J., Lin J. K. and Meng C. L. 1994. Expression of *p53* protein in nasopharyngeal carcinoma. *J. Pathol.* **172** 294-6.
- SHEU L. F., Chen A., Tseng H. H., Leu F. J., Lin J. K., Ho K. C. and Meng C. L. 1995. Assessment of *p53* expression in nasopharyngeal carcinoma. *Hum. Pathol.* **26** 380-6.
- SPRUCK C. H., Tsai Y. C., Huang D. P., Yang A. S., Rideout W. M., Gonzalez-Zulueta M., Choi P., Lo K. W., Yu M. C. and Jones P. A. 1992. Absence of *p53* gene mutations in primary nasopharyngeal carcinomas. *Cancer Res.* **52** 4787-90.
- SUN Y., Hegamyer G., Cheng Y. J., Hildesheim A., Chen J. Y., Chen I. H., Cao Y., Yao K. T. and Colburn N. H. 1992. An infrequent point mutation of the *p53* gene in human nasopharyngeal carcinoma. *Proc. natn. Acad. Sci. U.S.A.* **89** 6516-20.
- SZEKELY L., Selivanova G., Magnusson K. P., Klein G. and Wiman K. G. 1993. EBNA5, an Epstein-Barr virus-encoded nuclear antigen, binds to the retinoblastoma and *p53* proteins. *Proc. natn. Acad. Sci. U.S.A.* **90** 5455-9.

- VOUSDEN K. 1993. Interactions of human papillomavirus transforming proteins with the products of tumour suppressor genes. *FASEB J.* 7 872-9.
- YIP T. T., Ngan R. K., Lau W. H., Poon Y. F., Joab I., Cochet C. and Cheng A. K. 1994. A possible prognostic role of immunoglobulin G antibody against recombinant Epstein-Barr virus BZLF1 transactivator protein ZEBRA in patients with nasopharyngeal carcinoma. *Cancer* 74 2414-24.
- ZHANG Q., Gutsch D. and Kenney S. 1994. Functional and physical interaction between p53 and BZLF1: implications for Epstein-Barr virus latency. *Molec. cell. Biol.* 14 1929-38.

Accepted 5 January 2000